

Journal of the Hellenic Veterinary Medical Society

Vol 73, No 4 (2022)



Clinical and Molecular Epidemiological Study on Herpesviruses Infection among Equid Populations in Upper Egypt

A Abdel-Rady, I Abd El-Rahim, S. Gad El-Rab Abd El-Hameed, S Malek

doi: [10.12681/jhvms.28144](https://doi.org/10.12681/jhvms.28144)

Copyright © 2023, Ahmed Abdel-Rady, Safaa Malek, Salheen Abd El-Hameed



This work is licensed under a [Creative Commons Attribution-NonCommercial 4.0](https://creativecommons.org/licenses/by-nc/4.0/).

To cite this article:

Abdel-Rady, A., Abd El-Rahim, I., S. Gad El-Rab Abd El-Hameed, & Malek, S. (2023). Clinical and Molecular Epidemiological Study on Herpesviruses Infection among Equid Populations in Upper Egypt. *Journal of the Hellenic Veterinary Medical Society*, 73(4), 4689–4872. <https://doi.org/10.12681/jhvms.28144>

Clinical and Molecular Epidemiological Study on Herpesviruses Infection among Equid Populations in Upper Egypt

A. Abdel-Rady^{1,*}, I. Abd El-Rahim², S. Gad El-Rab Abd El-Hameed³, S. S. Malek¹

¹Infectious Diseases, Department of Animal Medicine, Faculty of Veterinary Medicine, Assiut University, Assiut, Egypt

²Department of Environmental and Health Research, Umm Al-Qura University, Makkah Al-Mukaramah, Saudi Arabia

³Private practitioner

ABSTRACT: The present study was carried out to record the clinical signs of equine herpesviruses (EHVs) infection and to detect the prevalence of EHVs infection among working equids in different provinces of Egypt. A total number of 115 working equids (92 horses and 23 donkeys) were clinically examined and sampled from November 2018 till November 2019 for this study.

Two samples were collected from each animal (nasal swab and blood sample) and were subjected to multiplex-PCR to detect the prevalence of different EHVs infection among equids.

In the current study, overall prevalence of EHVs infection among equid populations in Egypt was 80% by using multiplex-PCR. Moreover, the most prevalent equine herpesvirus (EHV) among equids in Upper Egypt was EHV-2 (61. 74%), followed by EHV-5 (43. 48%), EHV-1 (20%) and EHV-4 (13. 04%). The recorded clinical signs of the examined equids harbored EHVs (PCR-positive) can be summarized as follow: a higher percentage was detected among equids with a history of acute onset (59. 78%), pyrexia (57. 61%) and/or systemic illness (45. 65%) with or without respiratory signs (56. 52%) and ocular signs (35. 87%). Furthermore, 4. 35% and 1. 09% of EHV-1 PCR-positive equids displayed neurological signs and abortion, respectively.

Keywords: Working equids; Egypt; EHVs; Clinical signs; multiplex PCR.

Corresponding Author:

Ahmed Abdel-Rady, Infectious Diseases, Department of Animal Medicine, Faculty of Veterinary Medicine, Assiut University, PO Box 71526 Assiut, Egypt.
E-mail address: abdelrady14@aun. edu. eg

Date of initial submission: 06-10-2021
Date of acceptance: 03-08-2022

INTRODUCTION

Equine herpesviruses are ubiquitous pathogens in universal equid populations and can immediately become accustomed to infecting non-equid host species. EHV-1 typically remain in their hosts as a latent lifelong infection. After initial infection, the viruses remain in a state of latency in host neural tissue, and lymphoid cells. During viral latency there is little and continuous viral replication and minimal viral gene expression, despite the presence of the viral genome in the nucleus of infected cells. Virus recrudescence subsequently leads to viremia and shedding of infectious virus particles into the environment (Reese, 2016; Seeber, 2019). EHV-1 seems to be highly contagious with up to 100% transmission success upon direct contact with a virus shedder in horses (Allen *et al.*, 2008). Diagnosis, treatment, and prevention of EHV-1 are extremely confronting, partly as a consequence of the virus-host interactions complexity (Slater, 2014; Gulati *et al.*, 2019). Of the nine EHV-1s, which are alphaherpesviruses (EHV-1, EHV-3, EHV-4, EHV-6, EHV-8, and EHV-9) and gammaherpesviruses (EHV-2, EHV-5, and EHV-7), five subtypes of herpesviruses (EHV-1 to EHV-5) have been reported in horses, while donkeys are host to EHV-6 to EHV-8 (asinine herpesviruses, AHV-1 to AHV-3) and Thomson's gazelles, giraffe and zebras are hosts to the newest member of EHV-9 (gazelle herpesvirus) with encephalitis (Schrenzel *et al.*, 2008; Davison *et al.*, 2009; Greenwood *et al.*, 2012). Equine herpesvirus type-1 (EHV-1) and equine herpesvirus type-4 (EHV-4) are of great magnitude that pass on a disease to 80-90% of horses linked with respiratory infection (Allen, 2008). EHV-1 and EHV-4 are recurrent etiological causes associated with abortions (EHV-1, rarely EHV-4), respiratory (EHV-1 and EHV-4) and sporadic and epidemic outbreaks of neurological disease (EHV-1) known as equine herpesvirus myeloencephalopathy (EHM) (Goodman *et al.*, 2007; Pronost *et al.*, 2010).

Equine herpesvirus type-2 (EHV-2) and equine herpesvirus type-5 (EHV-5) initiate upper respiratory tract infection, inappetence and immunosuppression. Also, they are associated with keratoconjunctivitis, lymphadenopathy and general depression (Fortier *et al.*, 2010). EHV-5 is routinely detected in blood and nasal secretions of healthy horses and frequently does not cause disease in horses. In spite of this, recent articles correlate EHV-5 with lung infection leading to equine multinodular pulmonary fibrosis (EMPF) (Williams *et al.*, 2007; Hussey *et al.*, 2019).

In Egypt, although equids perform an influential role in Egyptian finances through direct and indirect economic impact of the horse industry, the epidemiology of EHV-1, its prevalence and distribution viral strains and risk factors predisposing to infection (El-Hage *et al.*, 2016; Khalil, 2017; Azab *et al.*, 2019). For that reason, estimation of the prevailing circumstances about the incidence of EHV-1 infection and associated risk factors of their continuation among working equids in Egypt is of great importance.

This study aimed to record the clinical signs of EHV-1 infection among working equids in Egypt, to detect the prevalence of EHV-1, -4, -2 and -5 among horses and donkeys' populations in Egypt by using multiplex PCR, and to study the relationship between EHV-1 infection and age, sex and season.

MATERIALS AND METHODS:

Animals

One hundred and fifteen equids (92 horses and 23 donkeys) were used as work and draft animals and from different localities in four Upper Egypt provinces (El-Menia, Assiut, Sohage and Luxor) were examined at the period from November 2018 till November 2019 for investigation of the prevalence of EHV-1 infection including sexes, ages and seasons.

The total number is 150 animals and the sample size calculated is 108 but we increase the number up to 115 to sample size to become more representative and calculation of sample size was according to the following link <https://goodcalculators.com/sample-size-calculator> :© 2015-2022 goodcalculators.com

The sample size (n) is calculated according to the following formula: $n = [z^2 * p * (1 - p) / e^2] / [1 + (z^2 * p * (1 - p) / (e^2 * N))]$

Samples

Two samples were collected from each examined animal (nasal swab and blood sample). Most of the samples were collected from animals with obvious clinical signs for less than 7 days before presentation (acute early febrile phase of respiratory infection). Whole blood samples were drained from each examined equid through jugular vein by using sterile vacutainer tube with ethylenediamine tetra-acetic acid (EDTA). Also, nasal swab samples (standard Sigma Virocult® swab - 15 cm long with a cellular foam buds) as the nasal swab pins were introduced via

the ventral nasal meatus to collect samples from the nasal mucosa and placed immediately into 3mL normal saline and the tubes were vortexed, centrifuged, and the supernatants were used directly. All samples were collected and transported to the laboratory for processing, preparation and investigation.

Clinical examination

Equids showing systemic signs, including a significant increase in body temperature (rectal temperature $>38^{\circ}\text{C}$ for donkeys and $>38.5^{\circ}\text{C}$ for horses), abortions, neurological signs (ataxia, paresis and paralysis) and/or respiratory manifestations and their contacts were clinically examined by measuring body temperature, respiratory rate, heart rate and mucous membranes according to Radostits et al. (2007).

DNA extraction and PCR

A commercial QIA amp DNA mini kit (Qiagen, Hilden, Germany) were used in accordance with the manufacturer's directions to extract DNA from collected blood samples and nasal swab samples. A multiplex-PCR targeting the highly conserved gB genes were used for detection of EHV-1 and EHV-4 and separate multiplex-PCR assay for detection of EHV-2 and EHV-5 were also done. PCRs were performed using EmeraldAmp® GT PCR Master Mix (Takara Bio Inc.). Each of the 25µl PCR mixtures contained 12.5µl of EmeraldAmp GT PCR (2x premix), 4.5 µl of PCR grade water, 1 µl of each forward and reverse primers and 2 µl of template DNA. In each reaction, negative control (nuclease-free water) and a positive control (vaccine for EHV-1 and EHV-4) were included. PCR amplification were performed by using specific virus primers for the detection of EHV-1 and EHV-4 (Kirisawa *et al.*, 1993), EHV-2, and EHV-5 (Holloway *et al.*, 1999; Diallo *et al.*, 2008) (Table 2). The region of targeting EHV-1 and EHV-4 gB genes was amplified with an initial denaturation step of 94°C for 5 min, followed by 40 cycles of denaturation at 94°C for 30 sec, annealing at 64°C for 30 sec, extension at 72°C for 1 min and 30 sec. and a final extension at 72°C for 10 min. While, EHV-2 and EHV-5 targeting region was amplified by an initial denaturation step of 95°C for 5 min, followed by 40 cycles of amplification, using denaturation at 95°C for 30 sec., annealing at 60°C and extension at 72°C for 45 sec and followed by a final extension at 72°C for 10 min. The final specific PCR products were visualized using 1.5% agarose gel electrophoresis. The gels were examined for specific size bands using transilluminator UVP, USA) and photographed using (BIORD UVP, USA).

Statistical analysis

Statistical analysis was performed using Pearson's chi square test to analyze tables with more than two variables. Fisher's exact test was used to analyze 2×2 tables. A P-value ≤ 0.05 was considered statistically significant. The significance of the differences in the incidence rate of the disease and risk factors was determined with a chi-square (χ^2) test. A P value of < 0.05 considered statistically significant. Odds ratios and the 95% confidence intervals were calculated using www.vassarstats.net.

RESULTS

Clinical abnormalities of the examined equids

Generally, clinical findings recorded among EHV PCR-positive equids included history of acute onset [(55/92); (59.78%)], [(53/92); (57.61%)], fever and/ or [(52/92); (56.52%)] respiratory signs (27.17% serous, 13.04% mucopurulent, 7.61% profuse mucopurulent nasal discharge, 6.52% mild dyspnea, 2.17% severe dyspnea and/or 18.48% cough), (45.65%) systemic illness (in appetite, depression and lethargy) and [(33/92); (35.87%)] ocular discharges Figures 1 & 2. Regarding the observed clinical signs on equids (EHV-1 PCR-positive), [4/92; (4.35%)] and [1/92; (1.09%)] displayed neurological signs and abortion, respectively, and the clinical signs were recorded as following: One sporadic horse was displayed pyrexia and respiratory manifestations followed by hind limbs paresis and recumbences (Dog sitting position). As shown in figure no. (4), and the other horse showed ataxia without any detectable clinical signs. Moreover, two donkeys showed signs of fever, ataxia and paresis of the hind limbs followed by death. In addition, one sporadic pregnant mare displayed signs of fever with depression, anorexia and respiratory signs ended by abortion in the last third of gestation period with the fetus still contained in the allantochorion (Figure3). Concerning the observed clinical signs on equids (EHV-2 and EHV-5 PCR-positive), they were commonly found with fever with and without respiratory signs, mild systemic illness, ocular discharge, as shown in figure 1 and 2. Moreover, one sporadic foal suddenly died without any obvious signs (EHV-5 PCR-positive) when postmortem examination was done, it showed large discrete nodules of fibrosis adjacent to grossly normal lung tissue appeared, suspected that foal may be had EMPF (Figure5). Figures 6, 7, 8 and 9 depict clinically affected or suspect animals that were confirmed as EHV-positive by multiplex PCR.



Figure (1): Respiratory disorders with serous nasal discharge of EHV-1 infected horse (PCR-positive)

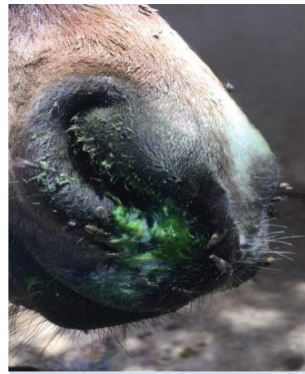

Figure (2): Respiratory disorders with mucoid nasal discharge from EHV-1 infected horse (PCR-positive) (greenish color represents food particles).



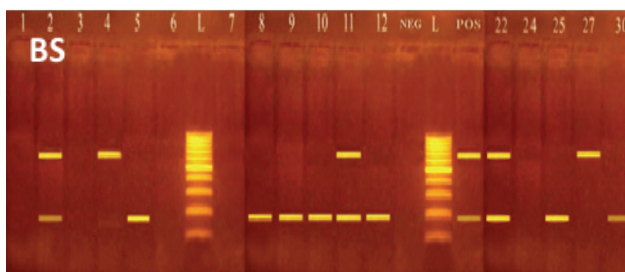

Figure (4): Dog sitting position, ataxia and hind limb paralysis in horse (EHV-1 PCR-positive)

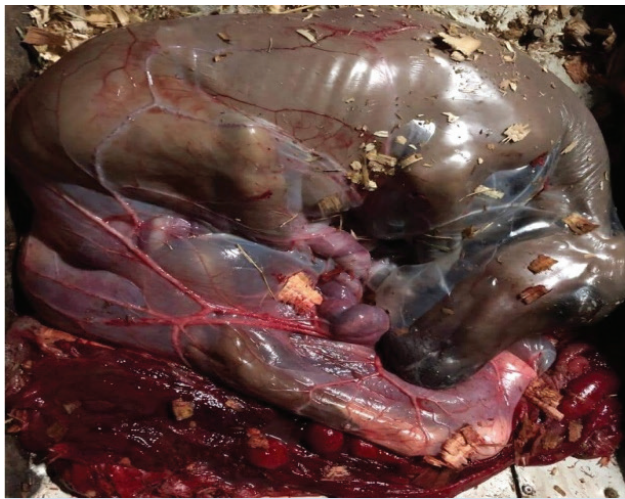

Figure (3): Dead aborted fetus still contained in the allantochorion close to term in pregnant mare (EHV-1 PCR-positive)

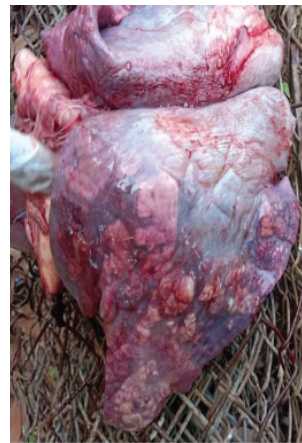

Figure (5): Gross postmortem of foal with equine multinodular pulmonary fibrosis (EMPF). Note the large discrete nodules of fibrosis adjacent to grossly normal lung tissue. (EHV-5 PCR-positive)



Figure(6): Agarose gel electrophoresis 1.5% showing multiplex PCR products of EHV-1 & EHV-4 in blood samples of horses and donkeys. **L:** Molecular weight marker 100 bp. **NEG:** -ve control (nuclease free water).

POS: +ve control (vaccine of EHV-1 & EHV-4). Lanes 2 & 5, lanes (8-12) of horses and lanes 22,25 & 30 of donkeys were PCR- positive for EHV-1 showing band at 190 bp. **Lanes 2,4,11** of horses and lanes 22 & 27 of donkeys were PCR-positive for EHV-4 showing band at 677 bp

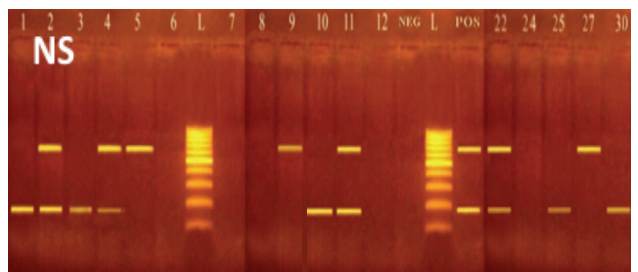


Figure (7): Agarose gel electrophoresis 1.5% showing multiplex PCR products of EHV-1 & EHV-4 in nasal swabs of horses and donkeys. **L:** Molecular weight marker 100 bp. **NEG:** -ve control (nuclease free water). **POS:** +ve control (vaccine for EHV-1 & EHV-4). Lanes (1-4), lanes 10 & 11 of horses and lanes 22,25 & 30 of donkeys were PCR-positive for EHV-1 showing band at 190 bp. **Lanes 2,4,5, 9 & 11** of horses and lanes 22 & 27 of donkeys were PCR-positive for EHV-4 showing band at 677 bp

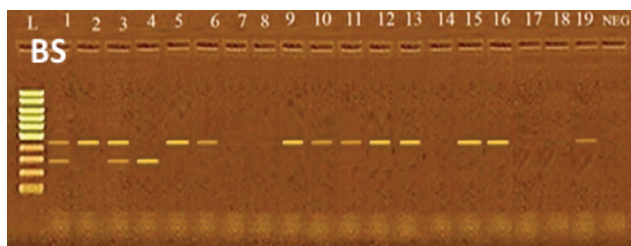


Figure 8: Agarose gel electrophoresis 1. 5% showing multiplex PCR products of EHV-2 & EHV-5 in blood samples of horses (1-19). **L:** Molecular weight marker 100 bp. **NEG:** -ve control (nuclease free water). **Lanes 1, 3 & 4** were PCR- positive for EHV-5 showing band at **293 bp**. **Lanes (1-3), 5 & 6, lanes (9-13) and lanes 15, 16 & 19** were PCR-positive for EHV-2 showing band at **444 bp**

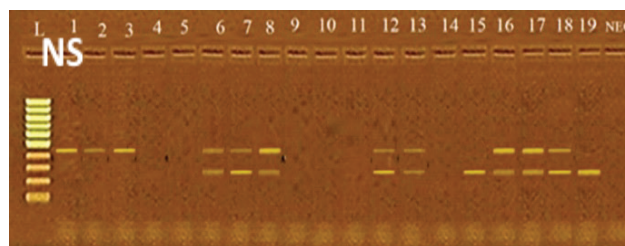


Figure 9:Agrose gel electrophoresis 1. 5% showing multiplex PCR products of EHV-2 & EHV-5 in nasal swabs of horses (1-19). **NEG:** -ve control (nuclease free water). **L:** Molecular weight marker 100 bp. **Lanes 6, 7, 8, 12 & 13 and lanes (15-19)** were PCR-positive for EHV-5 showing band at **293 bp**. **Lanes (1-3), lanes (6-8), lanes 12 & 13 and lanes (16-19)** were PCR-positive for EHV-2 showing band at **444 bp**

Prevalence of EHV-1, -4, -2 and -5 infections among equids by multiplex-PCR

Overall prevalence of EHV-positive equids was [(92/115); (80%)]. Moreover, the most prevalent virus was EHV-2 [(71/115); (61. 74%)], followed by EHV-5 [(50/115); (43. 48%)], EHV-1 [(23/115); (20. 00%)] and EHV-4 [(15/115); (13. 04%)]. Furthermore, EHV-4 was not detected in apparently healthy equids. In addition, apparently healthy donkeys were not harbored any of EHV's infection (Table 1.). A higher percentage of equids harbored EHV's was detected among clinically suspected group (89. 02%) when compared apparently healthy group (57. 57%) but the difference was not statistically significant ($P= 0. 1850$). Moreover, when individual viruses were considered, the results indicated significantly ($P= 0. 0001$) higher prevalence of EHV-2, significantly ($P= 0. 0202$) higher prevalence of EHV-4 and non-significant ($P= 0. 2753$) difference in the prevalence of EHV-1 and EHV-5 ($P= 0. 0902$) in equids displayed clinical signs

when compared to apparently healthy group, respectively (Table 1). In this study, although statistically non-significant different ($P= 0. 2933$ for EHV-1, $P= 0. 4080$ for EHV-4), a higher prevalence of EHV-1 (26. 09%) and EHV-4 (17. 39%) infections were detected in donkeys compared to horses as EHV-1 prevalence was 18. 48% and EHV-4 prevalence was 11. 96%. On the other hand, significantly ($P= 0. 0015$) higher prevalence of EHV-2 (71. 74%) and not significant ($P= 0. 1975$) higher prevalence of EHV-5 (47. 83%) were recorded in horses when compared to donkeys as EHV-2 prevalence was 21. 74% and EHV-5 prevalence was 26. 09% (Table 1).

Incidence of EHV's co-infections among equids as detected by multiplex PCR

Double and triple co-infections were detected for all EHV's in both clinically suspected and apparently healthy horses and donkeys (Table 2).

Table 1: Prevalence of EHV-1, -4, -2 and -5 infections among equids:

Samples	Equids	No. detected* (%)				Positive any EHV infections
		EHV-1	EHV-4	EHV-2	EHV-5	
Clinically Suspected	82	19	15	60	39	73
		(23. 17%)	(18. 29%)	(73. 17%)	(47. 56%)	(89. 02%)
Apparently Healthy	33	4	0	11	11	19
		(12. 12%)		(33. 33%)	(33. 33%)	(57. 57%)
Total	115	23	15	71	50	92
		(20. 00%)	(13. 04%)	(61. 74%)	(43. 48%)	(80. 00%)
Horses	92	17	11	66	44	78
		(18. 48%)	(11. 96%)	(71. 74%)	(47. 83%)	(84. 78%)
Donkeys	23	6	4	5	6	14
		(26. 09%)	(17. 39%)	(21. 74%)	(26. 09%)	(60. 87%)
Total	115	23	15	71	50	92
		(20. 00%)	(13. 04%)	(61. 74%)	(43. 48%)	(80. 00%)

* This includes virus detection in both nasal swabs and/or blood samples.

Table 2: Incidence of EHV's co-infections among equids as detected by multiplex PCR:

Classification	Virus	Nasal swabs	Blood samples
Unique detection	EHV-1 only	4	5
	EHV-4 only	5	4
	EHV-2 only	27	32
	EHV-5 only	11	15
Double detection	EHV-1 and EHV-4	2	0
	EHV-2 and EHV-5	23	11
	EHV-1 and EHV-2	6	6
	EHV-1 and EHV-5	1	1
Triple detection	EHV-1, -4 and -5	2	2
	EHV-1, -2 and -4	2	3
	EHV-2, -4 and -5	1	1

Table 3: Prevalence of EHV-1, -4, -2 and -5 infections among equids in relation to Age, Sex and Season:

Risk factors	Equids No.	No. detected* (%)			
		EHV-1	EHV- 4	EHV- 2	EHV-5
Age (years)					
≤ 1 year	16	2 (12. 50%)	3 (18. 75%)	13 (81. 25%)	9 (56. 25%)
1-5 years	27	10 (37. 04%)	5 (18. 52%)	18 (66. 67%)	16 (62. 96%)
5-10 years	24	4 (16. 67%)	3 (12. 50%)	10 (41. 67%)	7 (29. 17%)
10-15 years	23	3 (13. 04%)	2 (13. 04%)	11 (47. 83%)	7 (30. 43%)
≥ 15 years	25	4 (16. 00%)	2 (8. 69%)	19 (76. 00%)	10 (40. 00%)
Total	115	23 (20. 00%)	15 (13. 04%)	71 (61. 74%)	50 (43. 48%)
Sex					
Male	59	13 (22. 03%)	6 (10. 16%)	39 (66. 101%)	24 (40. 68%)
Female	56	10 (17. 86%)	9 (16. 07%)	32 (57. 14%)	26 (46. 43%)
Total	115	23 (20. 00%)	15 (13. 04%)	71 (61. 74%)	50 (43. 48%)
Seasons					
Spring	28	4 (14. 28%)	3 (10. 71%)	21 (75. 00%)	13 (46. 43%)
Summer	27	3 (11. 11%)	1 (3. 70%)	12 (44. 44%)	6 (22. 22%)
Autumn	26	9 (34. 61%)	6 (23. 08%)	15 (57. 69%)	10 (38. 46%)
Winter	34	7 (20. 59%)	5 (14. 70%)	23 (67. 64%)	21 (61. 76%)
Total	115	23 (20. 00%)	15 (13. 04%)	71 (61. 74%)	50 (43. 48%)

*This includes virus detection in both nasal swabs and/ or blood samples.

Prevalence of EHV-1, -4, -2 and -5 infections among equids in relation to Age, Sex and Season

Regarding the relationship between age of the examined equids and the prevalence of EHV infection in the current study, although the results were statistically non-significant for EHV-1 ($P=0.5648$), EHV-4 ($P=0.6385$) and EHV-5 ($P=0.0607$). Furthermore, significantly ($P=0.0380$) higher prevalence of EHV-2 (81.25%) was recorded at the age less than one year compared to the other age groups. As shown in table no. (3).

Concerning the relationship between sex of the examined equids and the prevalence of EHV infection in the present study, although the results were statistically non-significant for EHV-1 ($P=0.7044$), EHV-4 ($P=0.4803$), EHV-2 ($P=0.0775$) and EHV-5 ($P=0.1656$), a higher prevalence of EHV-1 (22.03%) and EHV-2 (64.41%) was recorded in male, while the higher prevalence of EHV-4 (16.07%) and EHV-5 (46.43%) was recorded in female. As shown in table no. (2).

DISCUSSION

Equine herpesviruses (EHVs) are frequent respiratory pathogens in horses and other equids globally and have been described to menace equid populations in Egypt (El-Hage *et al.*, 2016; Khalil, 2017; Azab *et al.*, 2019). Therefore, the aim of the current study was to detect the prevalence of the EHV infection among working equids in different Upper Egypt provinces by using multiplex PCR targeting the conserved region of gB genes for each specimen to identify EHV-1, -2, -4, and -5 with special reference to associated risk factors, such as age and, sex. Moreover, some equids were classified as positive only in nasal swabs, others in blood samples and some in both. Consequently, different kinds of discussion based on their clinical status (clinical signs or history) and type of sample (nasal swabs or blood samples) could be considered.

The data observed in the current study as well as previous studies clearly indicate that EHV is pervasive among equid populations in Egypt (Abd El-Hafez *et al.*, 2010; Amer *et al.*, 2011; Al-Shammari *et al.*, 2016 and Mohamed *et al.*, 2017; Azab *et al.*, 2019). The observed variation of the prevalence rate for each EHV strain among equids between studies probably is due to the different sampling distribution of associated risk factors (age, sex) in respective populations.

Concerning the observed clinical signs of the examined equids in the current study, EHV PCR-positive equids frequently appeared with a history of acute signs (59.78%), pyrexia (57.61%), and/or respiratory signs (56.52%), systemic illness (45.65%) and ocular discharges (35.87%); These observed signs were supported by Wood *et al.* (2007) who elucidated that EHV infection should be suspected when a horse suffered from one or more of the subsequent signs: lethargy, fever, inappetence, nasal discharge, swollen lymph nodes and occasionally coughing. Moreover, our findings are comparable within previous results of Wang (2003) who observed that 69% of EHV-positive horses had a history of acute disease and discovered that infected horses with EHV-1, EHV-2 and EHV-4 exposed commonly signs of 37% pyrexia and 49% mild systemic illness (lethargy, depression, and anorexia), presence of coughing (55%) or nasal discharge (26% mucoid or mucopurulent and 21% serous) were not of advantage for the recognition of EHV infected horses. In the current study, 56.52% of EHV PCR-positive equids displayed respiratory signs, four sporadic [(4/92); (4.35%)] equids had a neurological sign (EHV-1 PCR-positive), one sporadic abortion [(1/92); (1.09%)] and one sporadic death of a foal (EHV-5 PCR-positive) our observation agreed with previous reports of Wang *et al.* (2016) who reported that 50% of horses displayed respiratory disease and/or poor performance harbored EHV infection. Furthermore, the fore mentioned percentage of results Stasiak *et al.* (2018) who noted that 8% of EHV positive horses showed clinical signs of respiratory disease. Furthermore, the proportion of EHV-1 neurological disorders in this study was lower than previous reports of Pusterla *et al.* (2015) who elucidated that EHV-1 neurological deficits was (15.4%), and Raoofi *et al.* (2019) who revealed that 21.42% of EHV-1 qPCR-positive samples in Iran were established with history or clinical signs of neurologic disease. The aforementioned low abortion rate of EHV-1 (1.09%) was in concurrence with Silva *et al.* (2020) who recorded [2/105, (1.9%)] of equine abortions in Brazil caused by EHV1 infection.

Concerning the recorded clinical signs related to EHV-1, one of two horses of EHV-1 nervous manifestations, presented previous signs of pyrexia and respiratory signs followed by hind limbs paresis and recumbency (Dog sitting position), while the other horse showed acute onset of hind limb ataxia without any detectable clinical signs. Our results agreed with Salib *et al.* (2016) who reported that horses with

EHM showed dog sitting position. Furthermore, our results were in parallel with (Henninger *et al.*, 2007; Slater, 2014) who revealed that EHM may appear as a single sporadic case or as an outbreak and the infected horses displayed fever, lethargy and inappetence linked with acute onset of hind limb ataxia, toe dragging, hypotonia of the tail, recumbency and anal tone. The above mentioned records were in correspondence with previous studies described before by (Thiemann, 2012; Kapoor *et al.*, 2014; Sanctuary *et al.*, 2018) they elucidated that EHV-1 is concomitant with neurological diseases in donkeys and Negussie *et al.* (2017a) who defined Ethiopian epidemics of HM in donkeys, with deaths occurring without apparent clinical signs.

Concerning the recorded clinical signs related to EHV-1, one sporadic mare with abortion occurred in the last third of pregnancy, with fetus still contained in the allantochorion and the animal with history included fever, anorexia, depression and respiratory signs. This observation was supported by (Smith *et al.* 2003; Laugier *et al.* 2011) they reviewed that EHV-1 is the most prominent equine viral disease-initiating abortion with sporadic occurrences happened from latent virus reactivation, rather than from new EHV-1 infection. The above-mentioned results agreed with Ali *et al.* (2020) who recorded that clinical signs in one of two sporadic cases of EHV-1 aborted mares included anorexia with mild respiratory manifestation, while the other mare aborted without any detectable clinical signs. Our findings were in partial agreement with Slater (2014) who demonstrated that EHV-1 abortion occurring suddenly in the last third of pregnancy with the fetus still contained in the allantochorion is suggestive but not diagnostic of EHV-1 abortion.

Concerning the recorded clinical signs related to EHV-5, the sporadic sudden death of an apparently healthy foal was indicative of EMPF as the lung tissue developed large nodules of fibrosis on gross lesion after postmortem examination. Our observation was supported by (Hughes *et al.*, 2010; Schwarz *et al.*, 2013; Wilkins, 2013); Back *et al.*, 2016; Easton-Jones *et al.*, 2020) they shown that EMPF is a rare interstitial lung disease influencing horses at all ages and the etiology of EMPF. Is not fully clarified, but EHV-5 is expected to bear the main responsibility. Besides, our investigation was supported with previous reports of Wong *et al.* (2008) who reviewed that lungs of affected horses with EMPF Typically demonstrate interstitial fibrosis and mixed inflammatory in-

filtrates. Moreover, Scheurer *et al.* (2020) elucidated that EMPF should be included in the differential diagnosis of acute or chronic lower respiratory disease.

In the current study, 80% of the examined equids were PCR positive in at least one EHV strains when both samples were considered. Azab *et al.* (2019) who indicated that 69% of examined equids were positive for at least one of the four EHV by virus-specific qPCR registered higher prevalence rate of EHV infection among equids earlier in Egypt (Carlson *et al.*, 2013; Kapoor *et al.*, 2014). In addition, the highest percentage of EHV infection in the current study was comparable with prior study of Rushton *et al.* (2013) who found that 65% of horses were positive in consensus HV PCR in at least one in PBMCs, nasal- and conjunctival swabs.

About the equid's health status in the current study, non-significantly higher prevalence of EHV infection was detected among clinically suspect equids (89.02%) when compared with apparently healthy equids (57.57%). The higher prevalence among clinically suspect horses and donkeys in the current study was registered in previous studies of McBrearty *et al.* (2013) who recorded that 75% of horses with respiratory disease were positive for at least one virus of nasal swab PCR, and Laabassi *et al.* (2017) who detected that 90% of horses with respiratory disease harbored one or more of four EHV by qPCR.

Different results were reported by others as Negussie *et al.* (2017b) who recorded that EHV-1, -4, -2 and -5 prevalence in nasal swabs and blood samples from horses and donkeys with respiratory disease were 7.5%, 8.1%, 20.0% and 23.1%, respectively. Also, Laabassi *et al.* (2017) who authenticated that EHV-1, -4, -2 and -5 frequency in the nasal swabs of horses with respiratory disease were 2%, 14%, 90% and 75%, respectively; and Azab *et al.* (2019) who stated that EHV-1, -4, -2 and -5 prevalence in nasal swabs, blood samples, and lung tissues from clinically diseased equids in Egypt were 66.67%, 7.02%, 43.86% and 10.53%, respectively. Furthermore, in the current study EHV-4 was not detected among apparently healthy equids. This finding was coincided with previous reports of Negussie *et al.* (2017b) who reviewed that EHV-1 and EHV-4 were never detected among apparently healthy equids and EHV infection was never detected in apparently healthy donkeys and Seo *et al.* (2020) who elucidated that EHV-4 was not detected in any of the samples evaluated among apparently healthy horses. On the other hand, this re-

sult was in contrast to previous reports of Azab *et al.* (2019) who documented that all EHV-1 were detected in apparently healthy equids. In this study, apparently healthy donkeys weren't harbored any EHV-1 infection. This might be due to the small number of donkeys in this study.

Furthermore, the above mentioned results were in accordance with prior reports of Azab *et al.* (2019) who found that a greater frequency of EHV-1 (8/16; 50%) and EHV-4 (1/16; 6.25%) was identified in donkeys compared to horses EHV-1 (77/176; 43.75%) and EHV-4 (8/176; 4.5%). The greater epidemics of EHV-1 infection in donkeys might be correlated to Egyptian donkeys, which may be more susceptible to be infected with EHV-1, and/or donkeys are more exposed to a heavy workload, are generally in a poor nutritional state and have a heavy parasite burden.

Our results were in concurrence with previous reports of Negussie *et al.* (2017b) who elucidated that a significantly higher prevalence of EHV-2 and EHV-5 were recorded in horses (EHV-2 (25.2%); EHV-5 (28.6%)) compared to donkeys (EHV-2 (4.9%); EHV-5 (7.3%)). Also, the above-mentioned findings were in partial agreement with prior observations of Azab *et al.* (2019) who reported that a higher prevalence of EHV-2 (71/176) was detected in horses compared to donkeys (2/16), whereas a higher prevalence of EHV-5 (6/16) was detected in donkeys compared to horses (39/176). There is no evidence if the donkeys acquired EHV-1 infection from horses or whether they can be regarded as responsible for further spreading of the infection. Moreover, EHV-2 and EHV-5 detection in donkeys was coincided by previous reports of Negussie *et al.* (2017b) who was the first reporter of EHV-2 and EHV-5 among donkeys by virus specific PCRs, and Barrandeguy and Carossino (2018) who stated that gammaherpesvirus infections have been registered in donkeys and mules. Moreover, Azab *et al.* (2019) who reviewed that EHV-2 and EHV-5 were prevalent among donkeys in Egypt. This detection of EHV-2 and EHV-5 in donkeys highlighted the role of donkeys in EHV-1 epidemiology in Egypt.

Concerning to age groups, although a significant variation was not observed among the age groups with EHV-1, -4 and -5 infections, our data indicated that all age groups were susceptible to EHV-1 infection. Moreover, a higher prevalence of EHV-1 and EHV-5 was recorded at an age 1-5 years compared to the other age groups. Our observations were supported by previous reports of (Foote *et al.*, 2004; Patel and Hel-

dens, 2005; Bell *et al.*, 2006; Brault *et al.*, 2011; Hue *et al.*, 2014) they stating that epidemiological surveys suggest that EHV-1 infections contracts within first few weeks of life, mostly before or after weaning from adult horses. Also, latently infected lactating mares act as important reservoirs of the virus, infecting their foals in the initial stage of life. Furthermore, Pusterla *et al.* (2015) documented that the clinical expression of disease is often mild or remains subclinical, which could also explain the lower frequency of EHV-1 and EHV-4 detection between adult horses.

Regarding to sex groups in the current study, the highest prevalence of EHV-1 and EHV-2 was detected in males. There were differences in results among different studies such as findings recorded in previous studies of Bolfa *et al.* (2017) suggested that males are more susceptible to infections by EHV-1 and -4, while De Souza *et al.* (2017) and Negussie *et al.* (2017b) suggested a possible role of females in the continuance of the disease in the herd, as they are more susceptible to EHV-1 infection.

It is concluded that the current study was the first that detected EHV-1 infection among working equid populations in Upper Egypt provinces. It is necessary to perform more surveys in different regions of the country. These viruses are potential causes for respiratory diseases and loss in equine industry. Moreover, based on the current study more attention must be paid to existence of these viruses in equid populations in Egypt.

ACKNOWLEDGMENTS

The authors would like to introduce great thanks to the Deanship of Scientific Research at Umm Al-Qura University for supporting this work by Grant Code: (23UQU4320609DSR02).

CONFLICT OF INTEREST

The authors declare that they have no conflict of interests.

REFERENCES

- Abd El-Hafez, Y. G. M. ; Abu Maaty, A. , and Darwish, S. (2010): Isolation of equine herpesvirus-1 (EHV-1) as a cause of reproductive disorders with emphasis on antigenic and genetic identifications. *International Journal of Microbiological Research*, 1: 26-32.
- Ali, A. A. ; Refat, N. A. ; Algabri, N. A. , and Sobh, M. S. (2020): Fetal lesions of EHV-1 in equine. *Anais da Academia Brasileira de Ciências*, 92(2): 1-11.
- Allen, G. P. (2008): Risk factors for development of neurologic disease after experimental exposure to equine herpesvirus-1 in horses. *Am J Vet Res*. 69: 1595-1600.
- Allen, G. P. ; Bolin, D. C. ; Bryant, U. ; Carter, C. N. ; Giles, R. C. ; Harrison, L. R. ; Hong, C. B. ; Jackson, C. B. ; Poonacha, K. ; Wharton, R. , and Williams, N. M. (2008): Prevalence of latent, neuropathogenic equine herpesvirus-1 in the Thoroughbred broodmare population of central Kentucky. *Equine Vet. J.* 40: 105-110.
- Al-Shammari, Z. ; Ahmed, B. ; Haroun, M. ; Afify, A. ; Elsanousi, A. A. , and Shalaby, M. (2016): a first molecular phylogeny of an Egyptian equine herpesvirus-4 strain derived from a fetal Arabian horse. *Journal of Veterinary Science and Medical Diagnosis*, 5: 1-4.
- Amer, H. M. ; Shaltout, A. K. ; El-Sabagh, I. M. ; El-Sanousi, A. A. , and Shalaby, M. A. (2011): Prevalence of equine herpes viruses 1, 2 and 4 in Arabian horse population in Egypt. *African Journal of Microbiology Research*, 5(27): 4805-4811.
- Ann, N. ; Malik, M. ; Carlos, R. ; Arne, L. ; Vilmos, P. ; Duncan, H. ; Sándor, B. (2002): Prevalence of equine herpesvirus types 2 and 5 in horse populations by using type-specific PCR assays. *Vet. Res.* 33: 251-259.
- Ataseven, V. S. ; Bilge-Dagalp, S. ; Oguzoglu, T. C. ; Karapinar, Z. ; Güzel, M. , and Tan, M. T. (2010): Detection and sequence analysis of equine gammaherpesviruses from horses with respiratory tract disease in Turkey. *Transboundary and emerging diseases*, 57(4): 271-276.
- Azab, W. ; Bedair, S. ; Abdelgawad, A. ; Eschke, K. ; Farag, G. K. ; Abdel-Raheim, A. ; Greenwood, A. D. ; Osterrieder, N. , and Ali, A. A. (2019): Detection of equid herpesviruses among different Arabian horse populations in Egypt. *Veterinary medicine and science*, 5(3): 361-371.
- Back, H. ; Ullman, K. ; Leijon, M. ; Söderlund, R. ; Penell, J. ; Ståhl, K. , and Valarcher, J. F. (2016): Genetic variation and dynamics of infections of equid herpesvirus 5 in individual horses. *Journal of General Virology*, 97(1): 169-178.
- Barrandeguy, M. E. , and Carossino, M. (2018): Infectious diseases in donkeys and mules: an overview and update. *Journal of equine veterinary science*, 65: 98-105.
- Bell, S. A. ; Balasuriya, U. B. R. ; Gardner, I. B. A. ; Barry, P. A. ; Wilson, W. D. ; Ferraro, G. L. , and MacLachlan, N. J. (2006): Temporal detection of equine herpesvirus infections of a cohort of mares and their foals. *Vet. Microbiol.* 116: 249-257.
- Bolf, P. ; Jeon, I. ; Loftis, A. ; Leslie, T. ; Marchi, S. ; Sithole, F. ; Beck, C. ; Lecollinet, S. ; Zientara, S. ; Hans, A. , and Issel, C. J. (2017): Detection of West Nile Virus and other common equine viruses in three locations from the Leeward Islands, West Indies. *Acta Trop.* 174: 24-28.
- Braut, S. A. ; Bird, B. H. ; Balasuriya, U. B. , and MacLachlan, N. J. (2011): Genetic heterogeneity and variation in viral load during equid herpesvirus-2 infection of foals. *Veterinary microbiology*, 147(3-4): 253- 261.
- Carlson, J. K. ; Traub-Dargatz, J. L. ; Lunn, D. P. ; Morley, P. S. ; Kohler, A. ; Kasper, K. , and Lunn, K. F. (2013): Equine viral respiratory pathogen surveillance at horse shows and sales. *Journal of Equine Veterinary Science*, 33(4): 229-237.
- Damiani, A. M. ; Vries, M. ; Reimers, G. ; Winkler S. , and Osterrieder, N. (2014): A severe equine herpesvirus type 1 (EHV-1) abortion outbreak caused by a neuropathogenic strain at a breeding farm in northern Germany. *Veterinary Microbiology*, 172: 555-562.
- Davison, A. J. ; Eberle, R. ; Ehlers, B. ; Hayward, G. S. ; McGeoch, D. J. ; Minson, A. C. , and Thiry, E. (2009): The order Herpesvirales. *Archives of Virology* 154: 171-177.
- De Souza, M. D. C. C. ; Lara, H. ; Villalobos, E. M. C. ; Cunha, E. M. S. ; De Oliveira, J. V. ; de Castro Nassar, A. F. ; Silva, L. M. P. ; Okuda, L. ; Nogueira, A. H. C. ; Cunha, M. S. ; Marques, E. C. , and Mori, E. (2017): Occurrence of viral diseases in donkeys (*Equus asinus*) in São Paulo State, Brazil. *Brazilian Journal of Veterinary Research and Animal Science*, 54(2): 154-158.
- Diallo, I. S. ; Hewitson, G. R. ; de Jong, A. ; Kelly, M. A. ; Wright, D. J. ; Corney, B. G. , and Rodwell, B. J. (2008): Equine herpesvirus infections in yearlings in South-East Queensland. *Archives of virology*, 153(9): 1643- 1649.
- Easton-Jones, C. A. ; Cissell, D. D. ; Mohr, F. C. ; Chigerwe, M. , and Pusterla, N. (2020): Prognostic indicators and long-term survival in 14 horses with equine multinodular pulmonary fibrosis. *Equine Veterinary Education*, 32: 41-46.
- El-Hage, C. M. ; Mekuria, Z. M. ; Hartley, C. A. , and Gilkerson, J. R. (2016): Survey of equine herpesviruses -1, -2, -4 and -5 in 407 horses with and without respiratory disease. *Journal of Equine Veterinary Science* 39: S66-eS71.
- Foote, C. E. ; Love, D. N. ; Gilkerson, J. R. ; Wellington, J. E. , and Whalley, J. M. (2006): EHV-1 and EHV-4 infection in vaccinated mares and their foals. *Vet. Immunol. Immunopathol.* 111: 41-46.
- Fortier, G. ; Van Erck, E. ; Pronost, S. ; Lekeux, P. , and Thiry, E. (2010): Equine gammaherpesviruses: pathogenesis, epidemiology, and diagnosis. *The Veterinary Journal*, 186(2): 148-156.
- Goodman, L. B. ; Loregian, A. ; Perkins, G. A. ; Nugent, J. ; Buckles, E.

- L. ; Mercorelli, B. , and Davis-Poynter, N. (2007): A point mutation in a herpesvirus polymerase determines neuropathogenicity. *PLoS pathogens*, 3(11): 160.
- Greenwood, A. D. ; Tsangaras, K. ; Ho, S. Y. ; Szentiks, C. A. ; Nikolin, V. M. ; Ma, G. , and Osterrieder, N. (2012): A potentially fatal mix of herpes in zoos. *Current Biology*, 22(18): 1727-1731.
- Gulati B. R. ; Virmani N. , and Tripathi B. N. (2019): Equine Herpesviruses. In: Malik Y. , Singh R. , Yadav M. (eds) *Recent Advances in Animal Virology*. Springer, Singapore. 4:52-70.
- Henninger, R. W. ; Reed, S. M. ; Saville, W. J. ; Allen, G. P. ; Hass, G. F. ; Kohn, C. W. , and Sofaly, C. (2007): Outbreak of neurologic disease caused by equine herpesvirus-1 at a university equestrian center. *J. Vet. Intern. Med.* , 21(1): 157-165.
- Holloway, S. A. ; Lindquester, G. J. ; Studdert, M. J. , and Drummer, H. E. (1999): Identification, sequence analysis and characterization of equine herpesvirus 5 glycoprotein B. *Arch. Virol.* 144: 287-307.
- Hue, E. S. ; Fortier, G. D. ; Fortier, C. I. ; Leon, A. M. ; Richard, E. A. ; Legrand, L. J. , and Pronost, S. L. (2014): Detection and quantitation of equid gammaherpesviruses (EHV-2, EHV-5) in nasal swabs using an accredited standardized quantitative PCR method. *J. Virol. Methods*, 198: 18-25.
- Hughes, D. J. ; Kipar, A. ; Sample J. T. , and Stewart, J. P. (2010): Pathogenesis of a model gammaherpesvirus in a natural host. *J. Virol.* 84(8): 3949-3961.
- Hussey, G. S. ; Osterrieder, N. , and Azab, W. (2019): *Equine Herpesviruses. Reference Module in Life Sciences*. Elsevier Inc. , 1-9.
- Kapoor, S. ; Sharma, H. ; Singh, M. ; Kumar, P. ; Ranjan, K. ; Kumari, A. , and Khirbat, R. (2014): Equine herpesviruses: A brief review. *Advances in Animal and Veterinary Sciences*. 2 (2S): 46-54.
- Khalil, S. F. S. (2017): *Epidemiological and immunological studies on some viral equine infections causing reproductive problems in Egypt (Doctoral dissertation)*.
- Kirisawa, R. ; Endo, A. ; Iwai, H. , and Kawakami, Y. (1993): Detection and identification of equine herpesvirus-1 and -4 by polymerase chain reaction. *Vet. Microbiol.* 36: 57-67.
- Ko, S. ; Kang, J. G. ; Yeh, J. Y. ; Moon, J. S. ; Choi, G. C. ; Won, S. ; Chae, J. S. (2013): First report on molecular detection of equine upper respiratory infectious viruses in Republic of Korea. *J. Equine Vet. Sci.* , 33: 628-636.
- Laabassi, F. ; Hue, E. ; Fortier, C. ; Morilland, E. ; Legrand, L. ; Hans, A. , and Pronost, S. (2017): Epidemiology and molecular detection of equine herpesviruses in western Algeria in 2011. *Veterinary microbiology*. 207: 205-209.
- Laugier, C. ; Foucher, N. ; Sevin, C. ; Leon, A. , and Tapprest, J. (2011): A 24-Year Retrospective Study of Equine Abortion in Normandy (France). *J. Equine Vet. Sci.* , 31: 116-123.
- Lunn, D. P. ; Horohov, D. W. ; Osterrieder, K. , and Pusterla, N. (2009): EHV-1 Consensus Statement. *J. Vet Intern Med.* 23: 450-461.
- McBrearty, K. A. ; Murray, A. , and Dunowska, M. (2013): A survey of respiratory viruses in New Zealand horses. *New Zealand veterinary journal*, 61(5): 254-261.
- Mohamed, S. I. ; Shalaby M. A. ; El Deeb A. H. , and Salem, S. A. (2017): Prevalence of equine herpes viruses 1 and 4 in Arabian horses' population in Egypt. *Journal of Virological Sciences*, 2: 1-9.
- Murase, H. ; Miyazawa, M. ; Harada, T. ; Ozawa, M. ; Sato, F. , and Hada, T. (2017): Aborted fetal sizes of Thoroughbred horses in Hida, Japan, between 2005 and 2015. *Journal of equine science*, 28(2): 47-53.
- Negussie, H. ; Gizaw, D. ; Tessema, T. S. , and Nauwynck, H. J. (2017a): Equine herpesvirus-1 myeloencephalopathy, an emerging threat of working equids in Ethiopia. *Transboundary and emerging diseases*, 64(2): 389-397.
- Negussie, H. ; Gizaw, D. ; Tesfaw, L. ; Li, Y. ; Oguma, K. ; Sentsui, H. ; Tessema, T. S. , and Nauwynck, H. J. (2017b): Detection of equine herpesvirus (EHV)-1, -2, -4 and -5 in Ethiopian equids with and without respiratory problems and genetic characterization of EHV-2 and EHV-5 strains. *Transboundary and emerging diseases*, 64(6): 1970-1978.
- Patel, J. R. , and Heldens, J. (2005): Equine herpesviruses 1 (EHV-1) and 4 (EHV-4): Epidemiology, disease and immunophylaxis: A brief review. *Vet. J.* 170: 14-23.
- Pronost, S. ; Léon, A. ; Legrand, L. ; Fortier, C. ; Miszczak, F. ; Freymuth, F. , and Fortier, G. (2010): Neuropathogenic and non-neuropathogenic variants of equine herpesvirus 1 in France. *Veterinary microbiology*, 145(3-4): 329-333.
- Pusterla, N. ; Bain, F. ; James, K. ; Mapes, S. ; Kenelty, K. ; Barnett, D. C. ; Gaughan, E. ; Craig, B. ; Chappell, D. E. , and Vaala, W. (2017): Frequency of molecular detection of equine herpesvirus-4 in nasal secretions of 3028 horses with upper airway infection. *Veterinary Record*, vetrec- 2016.
- Pusterla, N. ; Mapes, S. ; Akana, N. ; Barnett, C. ; MacKenzie, C. ; Gaughan, E. ; Craig, B. ; Chappell, D. , and Vaala, W. (2015): Prevalence factors associated with equine herpesvirus type 1 infection in equids with upper respiratory tract infection and/or acute onset of neurological signs from 2008 to 2014. *Veterinary Record*, vetrec-2015.
- Radostits, D. M. ; Blood, D. and Gry, C. C. (2007): *Veterinary Medicine, A Textbook of the Disease of Cattle, Equine, Goats, Pigs and Camels*, the 8th Ed. ELBS and baillertindall:1145-1197.
- Raofi, A. ; Madadgar, O. ; Akbarein, H. , and Tazikeh, A. (2020): Molecular Detection and Phylogenetic Analysis of Equine Herpes Virus-1 in Horses with History or Clinical Signs in Four Provinces of Iran. *Iranian Journal of Veterinary Medicine*, 14(1): 27-35.
- Reese, T. A. , 2016: Coinfections: another variable in the herpesvirus latency-reactivation dynamic. *J. Virol.* 90: 5534-5537.
- Rushton, J. O. ; Kolodziejek, J. ; Tichy, A. ; Nell, B. , and Nowotny, N. (2013): Detection of equid herpesviruses 2 and 5 in a herd of 266 Lipizzaners in association with ocular findings. *Veterinary microbiology*, 164(1-2): 139-144.
- Salib, F. A. ; Kalad, M. A. ; Hassan, H. M. , and Said, S. F. (2016): Using indirect ELISA and PCR for the diagnosis of equine herpes virus-1 (EHV1) infection in Egypt. *Journal of Veterinary Medical Research*, 23(1): 117- 124.
- Sanctuary, D. ; Regis, S. ; Evans, L. , and Crane, M. (2018): *The Clinical Companion of the Donkey*, 1st ed. ; The Donkey Sanctuary: Devon, UK.
- Schrenzel, M. D. ; Tucker, T. A. ; Donovan, T. A. ; Busch, M. D. ; Wise, A. G. ; Maes, R. K. , and Kiupel, M. (2008): New hosts for equine herpesvirus 9. *Emerging infectious diseases*, 14(10):1616-1619.
- Scheurer, L. ; Bachofen, C. ; Herteman, N. ; Hilbe, M. ; Wolfer, N. , and Schoster, A. (2020): A case series highlighting the role of different gamma-herpesviruses in Equine Multinodular Pulmonary Fibrosis. *Schweizer Archiv für Tierheilkunde*, 162(4): 245-256.
- Schwarz, B. ; Klang, A. ; Bezdekova, B. ; Sárdi, S. ; Kutasi, O. , and Hoven, R. (2013): Equine multinodular pulmonary fibrosis (EMPF): five case reports. *Acta Veterinaria Hungarica*, 61(3): 319-332.
- Seeber, P. A. (2019): *Equid herpesvirus infections in zebras (Equus sp.) : host physiology and non-invasive detection of virus shedding (Doctoral dissertation)*.
- Seo, M. G. ; Ouh, I. O. ; Lee, S. K. ; Lee, J. S. ; Kwon, O. D. , and Kwak, D. (2020): Molecular Detection and Genetic Characteristics of Equine Herpesvirus in Korea. *Pathogens*, 9(2): 110-122.
- Slater, J. (2014): *Equine Herpesviruses*. In: Sellon DC, Long MT, editors. *Equine Infectious Diseases*. St. Louis, MO: Saunders. (8): 151-169.
- Silva, A. A. D. ; Villalobos, E. M. C. ; Cunha, E. M. S. ; Lara, M. D. C. C. D. S. H. ; Nassar, A. F. D. C. ; Piatti, R. M. ; Castro, V. ; Pinheiro, E. S. ; Carvalho, A. F. , and Fava, C. D. (2020): Causes of equine abortion, stillbirth, and perinatal mortality in Brazil. *Arquivos do Instituto Biológico*, 87.
- Smith, K. C. ; Blunden, A. S. ; Whitwell, K. E. ; Dunn, K. A. , and Wales, A. D. (2003): A survey of equine abortion, stillbirth, and neonatal death in the UK from 1988 to 1997. *Equine veterinary journal*, 35(5): 496-501.
- Stasiak, K. ; Dunowska, M. , and Rola, J. (2018): Prevalence and sequence analysis of equid herpesviruses from the respiratory tract of Polish horses. *Virology journal*, 15(1): 106.
- Thiemann, A. K. (2012): *Respiratory disease in the donkey*. *Equine Vet Educ.* 24: 469-478.
- Torfason, E. G. ; Thorsteinsdottir, L. ; Thorsteinsdottir, S. , and Svansson, V. (2008): Study of equid herpesviruses 2 and 5 in Iceland with a type-specific polymerase chain reaction. *Res. Vet. Sci.* 85: 605-611.
- Walter, J. ; Seeh, C. ; Fey, K. ; Bleul, U. , and Osterrieder, N. (2013): Clinical observations and management of a severe equine herpesvirus type 1 outbreak with abortion and encephalomyelitis. *Acta veterinaria*

- scandinavica, 55(1): 19-27.
- Wang, L. (2003): An investigation of the association between herpesviruses and respiratory disease in racehorses in Western Australia. PhD thesis, Murdoch University. (5): 112-135.
- Wang, L. ; Lievaart, J. ; Steel, C. M. , and Raidal, S. (2016): Identification of equine herpesviruses (EHV) in horses presented for evaluation of respiratory disease and/or poor performance. *Australian Equine Veterinarian*, 36(4): 48-58.
- Weber, R. ; Hospes, R. , and Wehrend, A. (2018): Causes of abortion in horses-overview of the literature and own evaluations. *Tierärztliche Praxis. Ausgabe G, Grosstiere/Nutztiere*, 46(1): 35-42.
- Wilkins, P. A. (2013): Equine multinodular pulmonary fibrosis: Diagnosis and treatment. *Equine Veterinary Education*, 25(8): 393-397.
- Williams, K. J. ; Maes, R. ; Del Piero, F. ; Lim, A. ; Wise, A. ; Bolin, D. ; Caswell, J. ; Jackson, C. ; Robinson, N. , and Derksen, F. (2007): Equine multinodular pulmonary fibrosis: A newly recognized herpesvirus-associated fibrotic lung disease. *Vet Pathol.* 44: 849-62.
- Wong, D. M. ; Belgrave, R. L. ; Williams, K. J. ; Del Piero, F. ; Alcott, C. J. ; Bolin, S. R. ; Marr, C. M. ; Nolen-Walston, R. ; Myers, R. K. , and Wilkins, P. A. (2008): Multinodular pulmonary fibrosis in five horses. *J. Am. Vet. Med. Assoc.* 232: 898-905.
- Wood, J. ; Smith, K. C. ; Daly, J. M. , and Newton, J. R. (2007): Viral infections of the equine respiratory tract. In *Equine respiratory medicine and surgery*. WB Saunders, 287-326.