

Arthroscopy of the fetlock joint of the dromedary camel

M. M. Ali¹; M. Abd-Elnaeim²

¹Assiut University, Faculty of Veterinary Medicine, Assiut, Egypt; ²Qassim University, College of Agriculture and Veterinary Medicine, Department of Veterinary Medicine, Buridah, Qassim, Saudi Arabia

Keywords

Dromedary camel, arthroscopy, fetlock joint

Summary

Objectives: To describe a technique for arthroscopy of the fetlock joint of the dromedary camel, and the problems that could occur during and after arthroscopy.

Methods: Seven animals (4 cadaveric limbs and 3 living camels) were used in this study. Two dorsal arthroscopic portals (lateral and medial) and one palmaro-lateral portal were used. Distension of the joint capsule was effected by injecting Ringer's lactate solution into the joint cavity. Landmarks for the dorsal arthroscopic portals were located at the centre of the groove bounded by the lateral branch of the suspensory ligament and the large metacarpus at a point 1 cm proximal to the joint. The palmaro-lateral portal was located in a triangular area between the branch of the suspensory ligament, the large metacarpus, and the sesamoid bone, with insertion of the arthroscope in a 45° joint flexion angle.

Results: Arthroscopy of the fetlock joint via

the dorso-lateral portal allowed examination of the distal end of the large metacarpus and the proximal end of the first phalanx of the fourth digit. Arthroscopy via a dorso-medial approach allowed examination of the distal end of the large metacarpus and the proximal end of the first phalanx and the distal end of the third digit. The palmaro-lateral portal allowed examination of the sesamoid bones, the synovial membrane, and the synovial villi. The main complications recorded during arthroscopy were iatrogenic articular surface injury as well as obstruction of vision with the synovial villi.

Clinical significance: This is the first work to describe the normal arthroscopy of the fetlock joint in the dromedary camel, the arthroscopic portals, and the complications that could occur during and after arthroscopy. Further studies are required for diagnosis of pathological changes in the fetlock joint of the dromedary camel and for arthroscopy of other joints in the dromedary camel.

synovial layer. The fibrous layer is attached around the margins of the articular surface. It is thick on the dorsal aspect although particularly absent on the palmar aspect. The synovial layer forms a dorsal and plantar (palmar) pouch (4-6).

The demand for arthroscopy in veterinary surgery is increasing as veterinarians and their clients become aware of its availability and effectiveness in diagnosis of various joint conditions (7-16). It can be used successfully in those joints in which synovitis, osteoarthritis and haemarthrosis cannot be diagnosed radiographically. Many surgical affections have been diagnosed in the fetlock joint of dromedary camel, including septic and aseptic arthritis, chip fracture of the proximal end of the first phalanx, synovitis, and osteoarthritis (7, 8).

According to the available literature, arthroscopy of the forelimb and hindlimb joints in the dromedary camel has not yet been reported. Arthroscopic studies of different joints in the dromedary camel are required to describe the normal and pathologic arthroscopic views of different joints in the dromedary camel to allow the practical use of arthroscopy in clinical diagnosis.

The objective of the present study was to describe the normal arthroscopic view of the fetlock joint in the dromedary camel as well as the problems that can occur during and after arthroscopy. This will accordingly support the use of arthroscopy for clinical diagnosis.

Materials and methods

Animals

Four cadaveric joint specimens and three anaesthetized dromedary camels (both forelimbs) were used for the study. The ca-

Introduction

Camels are animals of great importance in arid zones where they are used for food and transport (1, 2). In other areas they are popular zoo animals (3).

The fetlock joint in the dromedary camel is a compound joint with two articulations, one for each digit. It is formed by

the junction of the third metacarpal or metatarsal bones proximad, and the proximal phalanx distad. Paired sesamoid bones articulate with the palmar or plantar distal surface of the third metacarpal or metatarsal bones, and are rigidly fixed to the proximad-palmar or plantar edge of the proximal phalanx. The articular capsule is composed of an outer fibrous layer and a



Fig. 1 Landmarks for the arthroscopic portals: **A)** the dorsal portals (medial and lateral), and **B and C)** the palmaro-lateral portal.

daveric specimens were examined directly after euthanasia of the camels for conditions unrelated to the musculoskeletal system. Only fetlock joints that were considered clinically and radiographically normal were included in the *ex vivo* and *in vivo* study. Animals with clinical abnormalities of lameness and fetlock joint effusion were excluded. Latero-medial and dorso-palmar or dorso-plantar radiographic projections were obtained from each joint to ensure absence of any pathological radiographic changes. Exposure factors were 20–25 mAs, 55–65 KV at a focus film distance of 90–110 cm. Standard speed film and an intensifying screen were used. Animals that showed radiographic signs of abnormalities such as subluxation and luxation of the fetlock joint, as well as lesions of the articular surfaces were excluded from the study.

In vivo arthroscopic examination

All studies followed the Australian code of practice for the care and use of animals for scientific purposes, 7th Ed 2004, as far as arthroscopic examination of living animals was concerned. Prior to surgery, food was withheld for 12 hours and water for five hours to avoid complications with recumbency. Animals were anaesthetized with a combination of xylazine^a (0.25 mg/kg) and ketamine^b (5.5 mg/kg) administered intramuscularly (21). In addition lidocaine^c

(2%) was used for local infiltration at the incision site and for intra-articular injection of the fetlock joint just before the insertion of the trocar into the joint. The camel was placed in lateral recumbency, with the limb to be examined uppermost. The hair over the joint was clipped and the area was aseptically prepared using a povidone-iodine solution^d. The joint was slightly flexed. The site of the puncture was at the centre of the groove bounded by the lateral branch of the suspensory ligament and the large metacarpus at a point of 1 cm proximal to the joint. The joint was distended with 25–30 ml of lactated Ringer's solution. Resistance against the injection indicated complete filling of the joint cavity. The arthroscopic portal was made by creating a 1 cm skin incision using a number 11 scalpel blade. A sharp obturator was used to insert the arthroscope. The sleeve was advanced into the joint until fluid began to escape from the cannula. The sharp obturator was replaced with a 4 mm diameter, 25° forward-angled arthroscope^e. An ingress fluid line and glass fibre cable were attached to the arthroscope. The joints were viewed using a video camera^f and monitor. A 35 mm single lens reflex camera was used for photographic documentation. The joints were irrigated throughout the procedure with actated Ringer's solution delivered from a pressurized pump system. Pressure inside the joint was maintained between 150–200 mm Hg pressure. An 18-gauge, 38 mm needle

was placed on the opposite side of the arthroscope to be used as an egress cannula. Joint flexion at 45° was applied during insertion of the arthroscope. Complete joint examination required flexion and extension of the joint several times during the examination.

The dorsal recess of the fetlock joint was inspected first of all. Two dorsal arthroscopic portals (lateral and medial) (► Fig. 1A) were used for each joint. The arthroscope was inserted between the large metacarpus and suspensory ligament of each side (lateral and medial).

Another palmaro-lateral portal was then made for inspection of the palmar aspect of the joint cavity (► Fig. 1B, C), the sesamoid bone and its articulation with the metacarpus. This portal was located in a triangular area between the branch of the muscle interosseous medius, the metacarpus, and the sesamoid bone, with insertion of the arthroscope at a 45° angle. The arthroscope was rotated towards the palmaro-lateral aspect of the joint to examine the internal aspect of the synovial membrane and its extension. The joint was extended and flexed several times when the synovial villi severely disturbed visualization of the articular surface. After finishing the arthroscopic examination in the living animals, the joints were bandaged with a protective bandage for two days postoperatively and the animals received a prophylactic dose of ceftiofur sodium^g (2.2 mg/kg IM qd) for three days postoperatively.

^a Rompun: Arzneimittelvertrieb, Ascheberg, Germany

^b Arzneimittelvertrieb, Ascheberg, Germany

^c Almotaheda for trading and general supplies, Cairo, Egypt

^d Betadine: Mundipharma A.G., Basel, Switzerland

^e Richard Wolf GmbH, Knittlingen, Germany

^f Olympus Deutschland GmbH, Hamburg, Germany

^g Pfizer Deutschland GmbH, Berlin, Germany

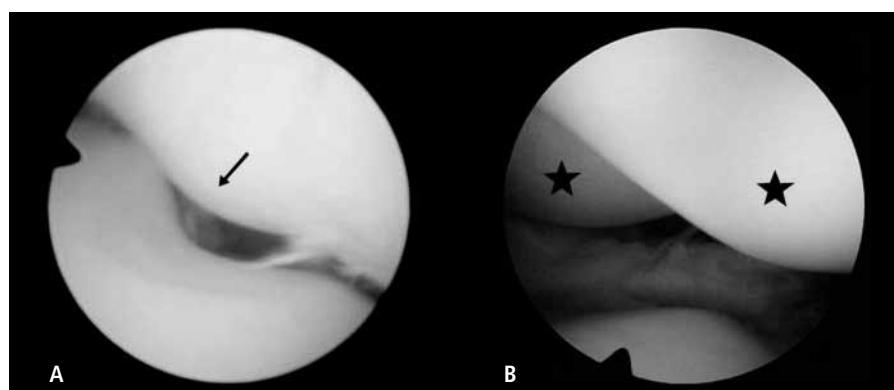


Fig. 2 Dorso-medial portal: A) The distal end of the large metacarpus forms an articular trochlea which has a sagittal ridge (arrow) for articulation with the first phalanx. B) The distal extremity of the large metacarpus (stars indicate the medial and lateral condyle).

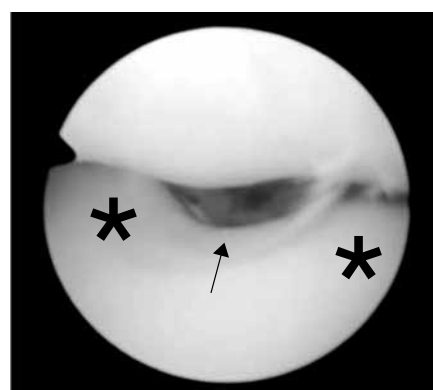


Fig. 3 Dorso-medial portal: The proximal articular surface of the first phalanx showed two facets (stars) separated by an intermediate sagittal groove (arrow).

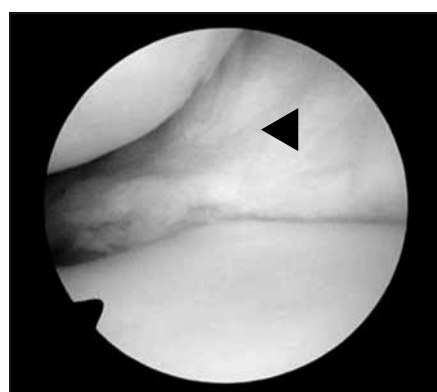


Fig. 4 Dorso-medial portal. The synovial layer of the joint capsule is spacious and thick (arrow head).

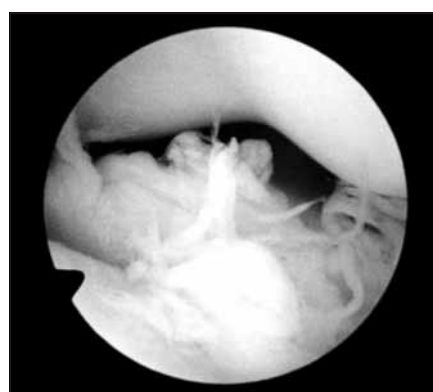

Fig. 5 Dorso-lateral portal: The synovial villi appeared flattened, numerous and pale in colour.

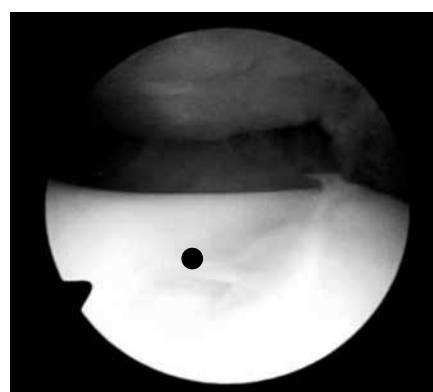

Fig. 6 Dorso-medial portal: The sesamoid bone carries an elongated articular surface for articulation with the palmar trochlea of the metacarpus (black spot).

Results

Ex vivo study

Arthroscopic examination of the fetlock joint from the dorso-medial and dorso-lateral portals

The lateral and medial joint sides were examined easily through insertion of the arthroscope from the dorsal portals with the joint in extended position. Movement of the arthroscope inside the joint in a slow careful rotatory movement allowed complete visualization of all joint structures. Joint structures that could be seen through these portals were the distal end of the large metacarpus (III & IV) and the proximal end of the first phalanx. Each division carries an articular trochlea which has a sagittal

ridge on its palmar aspect (►Fig. 2 A & B). The proximal articular surface of the first phalanx showed two facets separated by an intermediate sagittal groove (►Fig. 3). The articular surface appeared smooth, white in colour and glistening. The synovial layer of the joint capsule could be easily examined in the lateral aspect as it appeared spacious, and thick with extensions above and below the margins of the joint cavity to a distance of 1 cm (►Fig. 4). The synovial villi appeared flattened, thick and pale in colour (►Fig. 5). Repeated flexion and extension of the fetlock joint during arthroscopy allowed complete visual inspection of the joint structures, with exception of the palmar aspect of the joint which was better examined through the palmaro-lateral portal. Examination of the lateral joint angle was easier than the medial one.

Arthroscopic examination of the fetlock joint from the palmaro-lateral portal

Arthroscopy was done through the palmaro-lateral portal at a 45° joint flexion angle. The sesamoid bone carries an elongated articular surface for articulation with the palmar aspect of the trochlea of the metacarpus. The axial sesamoid is larger than the abaxial one. Each sesamoid bone articulated to one side of the intermediate ridge of the trochlea of the metacarpus. As this articulation lies deeper, it required deep insertion of the arthroscope into the joint cavity with flexion of the joint to a 45° angle to be visible (►Fig. 6). Moreover, the sesamoid bones articulate distally with the corresponding facet of the proximal phalanx base (►Fig. 7). The synovial mem-

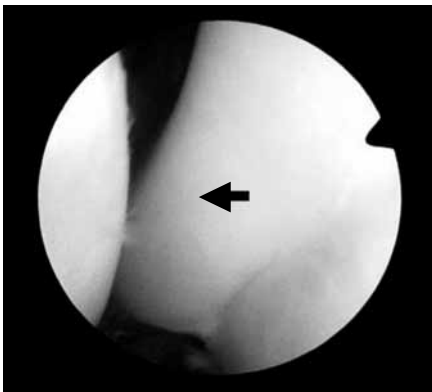

Fig. 7 Palmaro-lateral portal: The sesamoid bone articulates distally with the corresponding facet of the base of the proximal phalanx (arrow).

brane appeared smooth, pale rose in colour, and contained numerous rose-red coloured synovial villi (► Fig. 8). The synovial membrane extended 5 cm proximally, forming a proximal palmar pouch (► Fig. 9) and extended distally to a length of 2 cm forming a distal pouch.

In vivo study

The fetlock joint was examined in the living animals from the same portals used in the cadaveric study. The technique and the structures seen were the same as in the cadaveric study, however, movement of the joint in flexion and extension was difficult. This was clear especially during examination of the sesamoid bone. The arthroscopic portals healed without any complications in all the camels examined.

Complications

The main complications that occurred during arthroscopy were iatrogenic articular surface injury in three joints (two living animals and one joint specimen) (► Fig. 10), and disruption of vision by synovial villi movement in front of the lens. This was controlled by maintaining high pressure of the lavage fluid and by moving the joint in flexion and extension.

Discussion

Despite the importance of arthroscopy in the diagnosis and surgical treatment of many joint lesions, the available literature lacks any information about the normal and pathologic arthroscopic views of the joints in the dromedary camel. The present study aimed to describe the normal arthroscopic view of the fetlock joint in the dromedary camel as well as the complications that could occur during and after arthroscopy. The authors choose to study the fetlock joint because the joint is easy to examine in relation to its size and structure, and is easy to move in different directions during examination.

In our study, two arthroscopic portals were required for the insertion of the arthroscope on the dorsal aspect of the joint. This is due to the absence of communication between the articular cavities of the fetlock joint of the same limb (4, 5). Insertion of the arthroscope from the dorsal portals was easily performed when the joint

was fully distended and allowed complete arthroscopic examination of the lateral and medial angles of the fetlock joint. Maintaining complete distention of the joint capsule throughout the arthroscopic examination was important to allow inspection of all parts of the articular cavity (8, 12). The pressure inside the joint in this study was maintained between 150–200 mm Hg pressure. This pressure was suitable in examining the fetlock joint of the dromedary camel and appeared to allow complete distention of the joint capsule even with the large thickness of the skin of the camel. No complications from this pressure were recorded in our study, neither in the specimens nor in the living animals.

On the other hand, arthroscopic examination of the sesamoid bone required another portal through the palmaro-lateral aspect at a 45° angle. Flexion and extension of the joint during arthroscopy several times was important to allow complete visual examination of all joint structures; however examination of the lateral joint angle was easier than the medial one. This could be attributed to the greater size of the medial condyle of the large metacarpus versus the lateral one, which restricted the movement of the arthroscope inside the articular cavity (4, 22). Movement of the joint in flexion and extension was difficult in the arthroscopic examination of the living animals study due to the heavy weight of the animal. This can make the arthroscopic examination of the joint difficult and can result in destruction of the arthroscope while inserted in the joint; this is especially the case for the surgeons

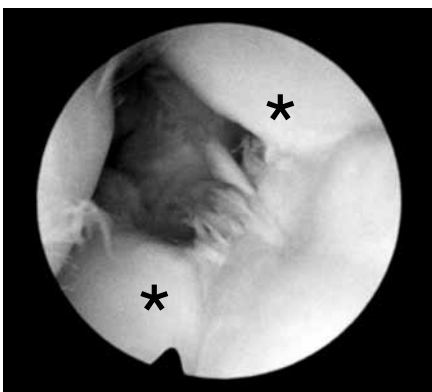


Fig. 8 Palmaro-lateral portal: Deep insertion of the arthroscope allows viewing of both sesamoid bones (stars).

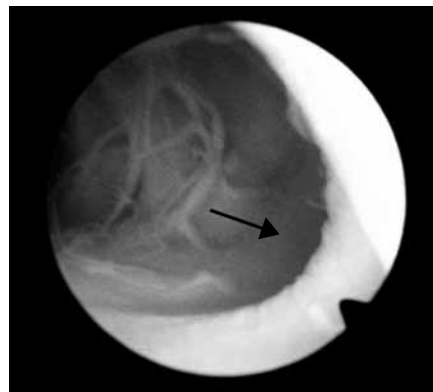


Fig. 9 Palmaro-lateral portal: The proximal pouch of the joint extends 5 cm proximal to the articular surface (arrow).

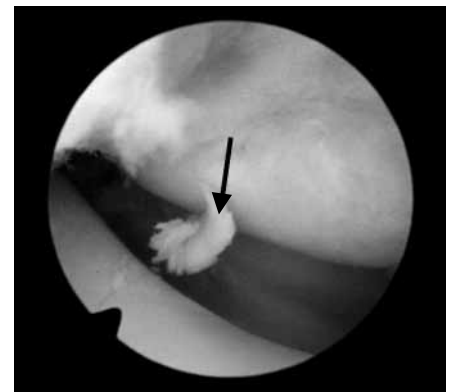


Fig. 10 Dorso-lateral portal: Iatrogenic articular surface injury (arrow).

who have little experience. The risk of this complication usually diminishes when the animals are examined under general anaesthesia and with surgeons who are experienced in the use of arthroscopy.

Potential complications of arthroscopy include scope tracts (cartilage indentations caused by trauma from the tip of the scope), damage to neurovascular structures, fluid extravasation and joint collapse, and scope dislodgement and breakage of instruments (6, 14). The main complication experienced in this study was iatrogenic articular surface injury. The cause of these injuries could not be ascribed to the use of the sharp trocar during penetration of the joint capsule as these defects appeared to be superficial. These injuries were thought to occur from the egress needle as a result of moving the joint in flexion and extension during the arthroscopic examination. These iatrogenic postoperative complications in the living animals. The second complication that occurred during arthroscopy was the disruption of vision in front of the lens with the synovial villi. However, maintaining high pressure of the fluid lavage and movement of the joint in flexion and extension directions appeared to be helpful in control of these complications.

Conclusion

Arthroscopy can be successfully used in examination of the fetlock joint in the dromedary camel. The present study attempted to describe the normal arthroscopic view of the fetlock joint in the dromedary camel as well as the complications that can occur during and after arthroscopy. Further studies are

required for diagnosis of pathological changes in the fetlock joint of the dromedary camel and for arthroscopy of other joints in the dromedary camel.

Acknowledgements

The authors would like to thank Mrs. Ina Gilchrist for the grammatical and spelling correction of this article.

Conflict of interest

None declared.

References

1. Wilson RT. Chapter 7: Camel, Llama, and Alpacas. In: *The Camel*. 1st ed. London: Longman Group; 1984. pg. 233–249.
2. Yagil R. In: *The Desert Camel*. 1st ed. Basel: Karger; 1985. pg. 122–140.
3. Ali BH. A survey of some drugs commonly used in the camel. *Vet Res Commun* 1988; 12: 67–75.
4. Karkoura AM. Surgical anatomical studies on the pes in the camels. MVS [Thesis]. Zakazik (Egypt): Zakazik University, Faculty of Veterinary Medicine; 1986.
5. Hifny A, Kassem AM, Enany EL, et al. Surgical anatomical study on the fetlock joint of camel Zakazik. *Vet J* 1987; 15: 28–41.
6. Ismail ZB, Al-Rukibat R. Synovial fluid cell count and total protein concentration in clinically normal fetlock joints of young dromedarian camels. *J Vet Med A Physiol Pathol Clin Med* 2006; 53: 263–265.
7. Gahlot TK. Lameness in camels. In: TK Gahlot, editor. *Proceedings of the International Camel Conference "Recent Trends in Camelids Research and Future Strategies for Saving Camels"*. Rajasthan, India; 2007 February 16–17. pg. 166–167.
8. Bani Ismail Z, Al Rukibat R. Synovial fluid cell counts and total protein concentration in clinically normal fetlock joints of young dromedarian camels. *J Vet Med a Physiol Pathol Clin Med* 2006; 53: 263–265.
9. McIlwraith CW, Yovich JV, Martin GS. Arthroscopic surgery for the treatment of osteochondral chip fractures in the equine carpus. *J Am Vet Med Assoc* 1987; 91: 531–540.
10. McIlwraith CW. Tearing of the medial palmar intercarpal ligament in the equine midcarpal joint. *Equine Vet J* 1992; 24: 367–371.
11. Kannegieter NJ, Colgan SA. The incidence and severity of intercarpal ligament damage in the equine carpus. *Aust Vet J* 1993; 70: 89–91.
12. Hoelzler MG, Millis DL, Francis DA, et al. Results of arthroscopic versus open arthrotomy for surgical management of cranial cruciate ligament deficiency in dogs. *Vet Surg* 2004; 33: 146–153.
13. Bubenik LJ, Johnson SA, Smith MM, et al. Evaluation of lameness associated with arthroscopy and arthrotomy of the normal canine cubital joint. *Vet Surg* 2002; 31: 23–31.
14. McIlwraith CW. Diagnostic and surgical arthroscopy of the metacarpophalangeal and metatarsophalangeal joints. In: CW McIlwraith, Nixon AJ, Wright IM, et al, editors. *Diagnosis and surgical arthroscopy in the horse*. 3rd ed. Philadelphia: Elsevier; 2005. pg. 129–196.
15. Munroe GA, Cauvin ER. The use of arthroscopy in the treatment of septic arthritis in two highland calves. *Br Vet J* 1994; 150: 439–449.
16. McCarthy TC. Arthroscopy. In: *Veterinary Endoscopy for the Small Animal Practitioner*. Elsevier; 2005. pg. 447–556.
17. Moore RM, Schneider RK. Arthroscopic findings in the carpal joints of lame horses without radiographically visible abnormalities: 41 cases (1986–1991). *J Am Vet Med Assoc* 1995; 206: 741–746.
18. McIlwraith CW, Wright IM, Nixon AJ, et al. Diagnostic and surgical arthroscopy of the femoropatellar and femorotibial joints. In: *Diagnostic and Surgical Arthroscopy in the Horse*. 3rd ed. Philadelphia: Elsevier; 2005. pg. 197–268.
19. Van Bree H, et al. Diagnostic and Surgical Arthroscopy in Small Animals. In: Mertens P, Hämmerling R, Korbel R, editors. *Jahrestagung der Fachgruppe Kleintierkrankheiten der DVG: 46. Jahreskongress der FK-DVG; 2000 November 9–12; Düsseldorf, Germany. Veterinärmedizinische Messe, VET-MESSE, Volume 46*. pg. 57–60.
20. Casscells WS. Arthroscopy of the knee joint. *J Bone Joint Surg* 1971; 53: 287–298.
21. White RJ, Bali S, Bark H. Xylazine and ketamine anaesthesia in the dromedary camel under field conditions. *Vet Rec* 1987; 120: 110–113.
22. Crisan M, Damian A, Dezdrobitu C, et al. Comparative Studies of Pelvic Limb Skeleton in Camel, Cow and Mare. *Bulletin from the University of Agricultural Sciences and Veterinary Medicine. Bucharest, Romania*; 2009; 66: 34–41.