

Use of biodegradable plates and screws in the treatment of pediatric facial bone fractures

Ahmed A.A. Ali^a, Mansour M. Kabbash^b, Samia M.A. Said^c,
Mohamed A. Shoeib^c and Mohamed H. Osman^d

Background Pediatric patients with facial fractures are a unique challenge in terms of their treatment planning, which is different from that of adult patients. Early literature has advocated conservative closed management of pediatric facial fractures to prevent complications. However, recent advances in treatment have enabled us to use biodegradable plates and screws, which overcome the limitations of metallic plates.

Aim This study was conducted to evaluate the effectiveness of Inion CPS biodegradable plates and screws on pediatric facial fractures.

Patients and methods The study was conducted on 30 pediatric patients with maxillofacial fractures requiring open reduction and internal fixation. Fractures with infection and comminuted fractures were excluded. Patients were aged 3–12 years, 18 boys and 12 girls, with different types of trauma: 12 patients had suffered falls, 12 patients had middle cerebral artery (MCA), four patients had sports-related fracture; and two patients had assault-related fractures. The site of fracture was different: 18 patients had mandibular fractures, four patients had zygomatic complex fractures, four patients had orbital fractures, two patients had maxillary fractures (one isolated and the other with mandibular fracture), and one patient had frontal bone and sinus fractures (anterior wall). Fractures were plated with a biodegradable system (Inion CPS) using standard plating principles. Postoperative complications were assessed.

Results Satisfactory reduction was obtained in all patients, as judged from the position of the fracture segments in

24-h postoperative radiographs compared with all subsequently obtained images. The undisturbed reduction was considered as a marker of the stable fixation provided by the bioresorbable system. The screw holes visible as radiolucencies on the radiograph were also seen to maintain their position throughout the period of follow-up.

Conclusion In our study, we concluded that the use of Inion bioresorbable plates is effective in the treatment of facial fracture in pediatric patients. There was no complication and no growth disturbance in the follow-up period, which proves that bioresorbable plates provide stable fixation in children. Our data support the use of bioresorbable plate fixation in pediatric craniofacial surgery as a means of avoiding the potential and well-documented problems associated with rigid metal fixation. *Egypt J Oral Maxillofac Surg* 7:86–93 © 2016 The Egyptian Association of Oral & Maxillofacial Surgeons.

Egyptian Journal of Oral & Maxillofacial Surgery 2016, 7:86–93

Keywords: biodegradable plate and screw system, internal fixation, pediatric facial fractures

^aDepartment of Plastic Surgery, Qena Faculty of Medicine, South Valley University, Qena, ^bDepartment of General Surgery, Aswan Faculty of Medicine, Aswan University, Aswan, ^cDepartment of Plastic Surgery, Sohag Faculty of Medicine, Sohag University, Sohag and ^dMaxillofacial Surgery Unit, Department of General Surgery, Assuit Faculty of Medicine, Assuit University, Assuit, Egypt

Correspondence to Mohammed H. Osman, MD, Maxillofacial Surgery Unit, Department of General Surgery, Assuit Faculty of Medicine, Assuit University, Assuit 71515, Egypt
Tel: +20 122 397 1586;
e-mail: mh.osman@yahoo.com

Received 1 February 2016 accepted 1 March 2016

Introduction

Treatment of maxillofacial trauma in the pediatric patient presents unique challenges that are not encountered in adults. Clinicians must consider distinct anatomic and physiologic differences in the growing facial skeleton when managing these problems. Some fundamental adult facial fracture treatment techniques (e.g. permanent titanium plating) are contraindicated in the pediatric population due to dental development and differential craniofacial growth patterns. Over the last several years, the refinement of rigid internal fixation has revolutionized the surgical management of craniofacial fractures; however, the effects of rigid fixation on craniofacial growth are not completely understood [1].

Rigid internal fixation with metallic materials is a standard technique in use for the last 35 years and is performed to align bone segments during healing periods. However, there are inherent drawbacks associated with metallic devices, such as susceptibility to corrosion, need

to remove these plates and screws due to infection, stress shielding, plate palpability, temperature sensitivity, interference with advanced imaging technique, possible growth restrictions and implant migration in the pediatric population, and problems in patients who have to be irradiated as they may cause backscatter [2].

In an effort to overcome the disadvantages of metallic osteofixation devices, various biodegradable polymers have been developed [3]. The advantages of biodegradable osteosynthesis devices include the gradual transference of physiological forces to the healing bone, the reduced need for a second operation to remove the material, its potential to serve as a vehicle to deliver bone healing proteins to fracture and osteotomy sites [4], and no growth restrictions or possible migration in growing patients. The implant degrades naturally and totally after the fracture has healed, thus preventing the stress shielding effect [5], while fibrous tissues or bone fills the space previously occupied by the implant [6]. Ideally,

these materials are sufficiently rigid, biocompatible, and provide stability without affecting bone healing and bone strength adversely, with no interference with postoperative imaging techniques or radiotherapy. Today most commercially available materials that have optimal characteristics for use as a fixation modality in maxillofacial trauma are copolymers consisting of polylactide acid (80–82%) and polyglycolic acid (18–20%).

However, first these have not been recommended for use in loaded and functional bone such as adult mandible because of the lower strength and stiffness of the material. The present study was undertaken to evaluate the efficacy of biodegradable plates and screws as a method for internal fixation in pediatric patients with maxillofacial fractures to study the morbidity associated with the use of these devices [7].

Patients and methods

This prospective study was conducted from October 2010 to October 2014 (4-year duration) on patients admitted to Upper Egypt university hospitals (Sohag and Assiut University Hospitals), to evaluate the effectiveness of Inion CPS (Inion, Tampere, Finland) biodegradable plates and screws on pediatric facial fractures. Thirty patients were treated, aged from 3 to 12 years, from both sexes (18 boys and 12 girls). Different mechanisms of trauma were recorded (12 patients who had suffered falls, 12 patients with motor car accident-related trauma, four patients with sports-related trauma, and two patients with assault-related trauma), with different fracture sites: 18 patients with mandibular fractures, five patients with zygomatic complex fractures, four patients with orbital fractures, two patients with maxillary fractures (one isolated and the other with mandibular fracture), and one patient with frontal bone and sinus fractures (anterior wall). All of them fulfilled the following inclusion criteria:

- (1) Onset of trauma within 1 week.
- (2) Nonheavily contaminated fractures.
- (3) Noncomminuted fractures
- (4) No systemic or medical diseases that affect bone healing.
- (5) Informed consent.

Exclusion criteria were the following:

- (1) Onset of trauma earlier than 1 week.
- (2) Heavily contaminated fractures.
- (3) Comminuted fractures.
- (4) Dental and dental–alveolar fractures.
- (5) Systemic or medical diseases that affect bone healing.

First, after admission to the trauma unit, all patients underwent preoperative assessment (primary survey) for trauma as per ATLS (advanced trauma life support), including the assessment of airways, breathing, circulation, disability, presence of associated life-threatening injuries, and other injuries that require urgent interference. Thereafter, they underwent history and physical examination (secondary survey) as per a special trauma

data sheet. History included personal data (name, age, sex, address), history of trauma [mechanism of trauma, time from trauma to first seen, any loss of consciousness or vomiting, any interference until arrival at the trauma unit, last meal or drink, and presence of comorbidities (medical disease and allergies)]; Polytrauma patients underwent AMPLE (Allergies, Medications, Previous diseases and surgeries, Last meal, Events/Environment surrounding the injury) history. Clinical examination began with assessment of the general condition of the patient, followed by local examination of the maxillofacial region. Finally, radiological examination was performed using computed tomography (CT) and panorex (for maxillary and mandibular fractures). After ensuring that the patients were medically stable they were operated upon, usually not more than 1 week from the onset of trauma (to avoid callus formation).

Materials

Biodegradable Inion CPS Plating System approved by the Food and Drug Administration was used as a method of internal fixation (Fig. 1) [8]. The material is a copolymer made of L-lactide acid, poly-D-lactide acid, trimethyl carbonate, and polyglycolic acid. These plates have been reported to resorb slowly, maintaining 70% of their initial strength at 9–14 weeks, with 42% bulk resorption by 40 weeks, and are completely resorbed within 2–4 years. Plates are malleable after activation in the Inion Thermo water bath (INION OY Lääkärintäti 2 FI-33520 Tampere, Finland) (55°C). After water bath treatment, plates are most malleable for 10–15 s for easy adaptation. They can also be reheated for further contouring or bent once cooled and can be easily cut with scissors.

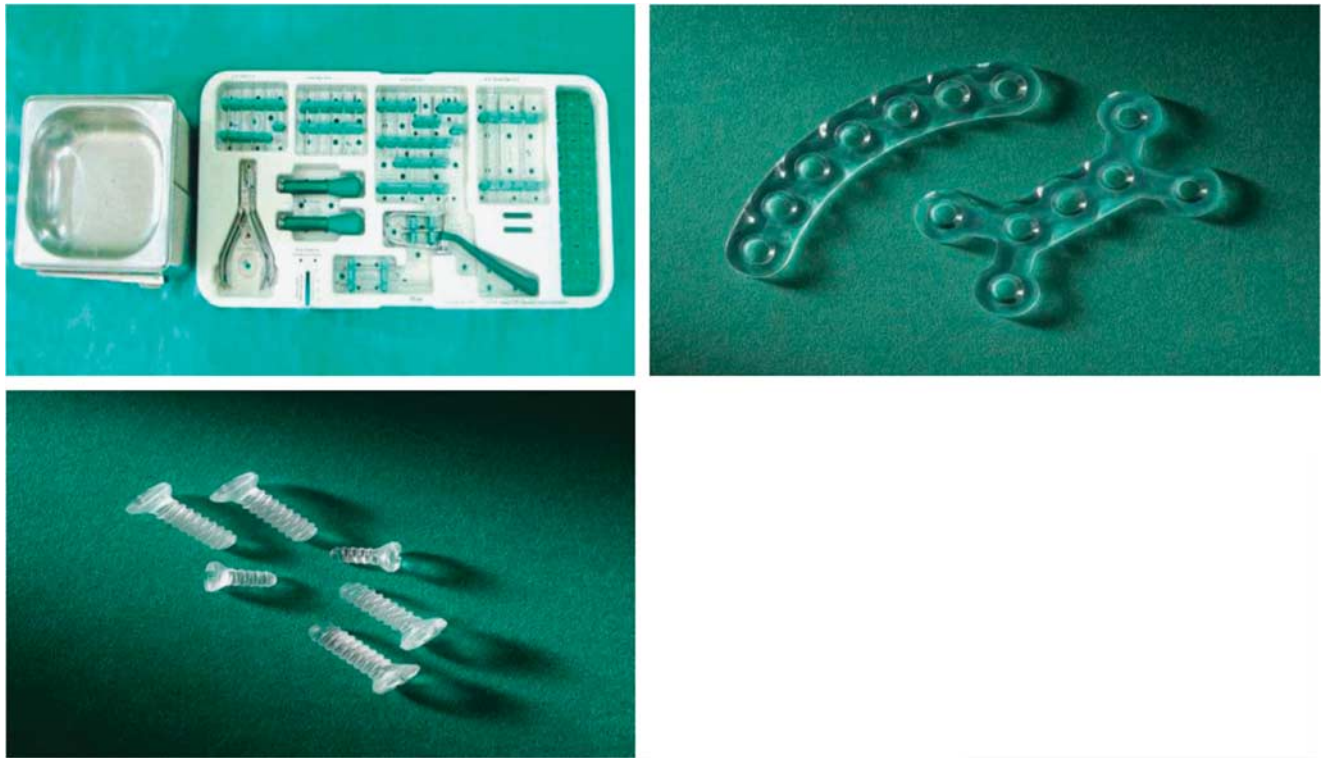
Surgical procedures

Surgical access was gained either through an existing skin laceration or following a standardized surgical approach. Reduction of fracture segments was achieved and segments were stabilized for plate fixation under general anesthesia. Intravenous antibiotics were injected during operations such as penicillins and cephalosporins.

There were 18 patients with mandibular fractures (12 patients with multiple fractures and six patients with single fractures), with a total of 30 (six condyle, six angle, seven body, seven parasymphiseal, and four symphiseal fractures) fractures operated upon (Table 1). Figure 2 shows patient 10 with intraoperative fracture exposure and fixation and Fig. 3 shows the preoperative CT. Maxillomandibular fixation (MMF) with arch bar was performed for cases with condylar fractures and multiple fractures to achieve proper fracture reduction and proper occlusion. The MMF was left postoperatively for 7–10 days in cases with condylar fractures in order to maintain occlusion. In patients with isolated mandibular fractures, interdental wires were applied for fracture reduction and removed after 2 weeks. Only one patient had no MMF or interdental wiring.

Totally, five patients presented with zygomatic complex fractures, from both sexes (three male and two female patients), with different etiologies (two falls and three MCA). There were three patients with right zygomatic

Fig. 1



Inion biodegradable system 8.

Table 1 Patients with mandibular fractures

Patient nos	Age (years)	Sex	Etiology	Fracture site	MMF (arch bar)		
					Intraoperative	Postoperative	Interdental wiring
1	7	Male	Fall	RT parasymphiseal + LT condyle	+	+	-
2	3	Male	Fall	LT body + RT condyle	+	+	-
3	4	Male	MCA	LT body + RT angle	+	-	-
4	9	Female	Fall	RT body + LT angle	+	-	-
7	12	Male	Assault	RT parasymphiseal + LT condyle	+	+	-
9	3	Female	Fall	Symphiseal + RT condyle	+	+	-
10	11	Male	MCA	RT parasymphiseal + LT angle	+	-	-
12	4	Female	Fall	Symphiseal + RT condyle	+	+	-
16	10	Female	Fall	RT parasymphiseal	-	-	+
17	11	Male	Sport	RT body	-	-	+
18	12	Female	MCA	LT angle + RT parasymphiseal	+	-	-
20	10	Male	Sport	LT parasymphiseal	-	-	+
22	9	Female	MCA	LT body	-	-	+
23	12	Male	Fall	Symphiseal	-	-	+
25	11	Female	Sport	RT body + LT parasymphiseal	+	-	-
28	4	Female	MCA	RT body + LT condyle	+	+	-
29	10	Male	MCA	LT angle	-	-	-
30	5	Male	Fall	LT angle + symphiseal	+	-	-

LT, left; MCA, middle cerebral artery; MMF, maxillomandibular fixation; RT, right.

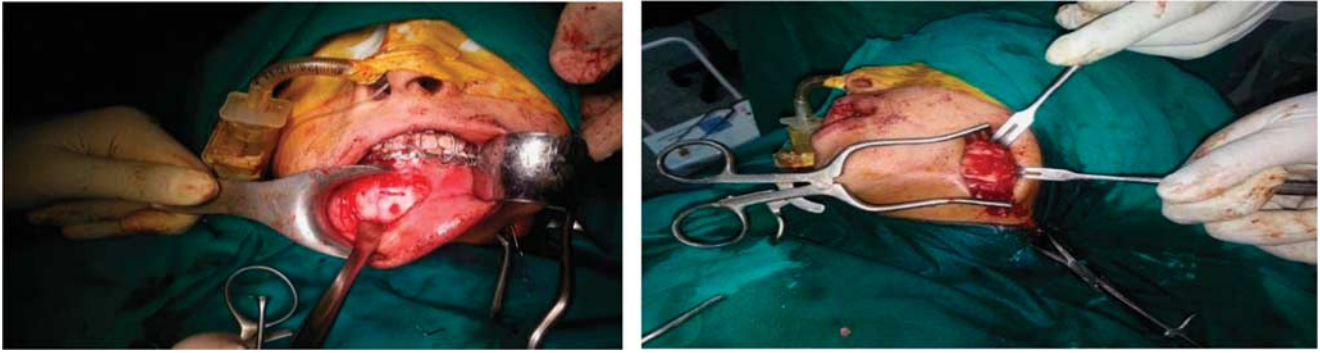complex fractures and two with left zygomatic complex fractures. Fixation at different points at the zygomatico-frontal suture, infraorbital rim zygomaticomaxillary buttress, was performed. Figure 4 shows patient 27 with a right zygomatic complex fracture in whom fixation was done at one point (at zygomaticomaxillary buttress). Figure 5 shows the preoperative CT.

Patients with orbital fractures were all male, with different types of trauma: two MCA, one sport injury,

and one assault). There were three with right orbital floor fractures and one with left orbital roof fracture. Reconstruction of the orbital floor was done with Inion CPS resorbable mesh and calverial bone grafts.

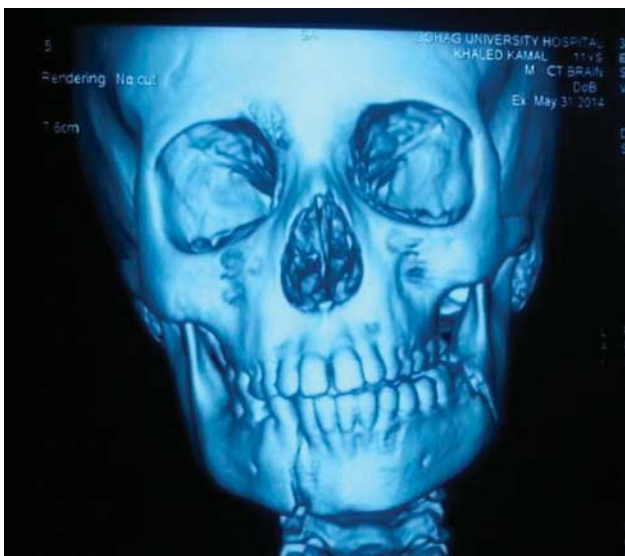There were two patients with maxillary fractures: one patient had right maxillary (Le Fort I) oblique fracture and was associated with mandibular fracture (right mandibular body fracture) and one patient had only right maxillary (Le Fort I) oblique fracture.

Fig. 2



Intraoperative view showing the site of fracture and fixation.

Fig. 3



Preoperative computed tomography scan showing the site of fracture.

There was only one male patient with left anterior wall frontal sinus fracture displacement associated with supraorbital rim and orbital roof fracture due to motor car accident.

The patients were followed up clinically and radiologically through frequent visits at outpatient clinics (1 week, 1 month, 3 months, 6 months, and 1 year): clinically to reveal wound healing complications and fracture segment stability and radiologically by CT for osseous healing, screw-hole ossification, and fracture union complications.

Results

This prospective study included 30 patients aged 3–12 (mean age: 7.5) years. There were five (16.7%) patients under the age of 5 years and 25 (83.3%) patients aged 5–12 years (Fig. 6). This difference is because children are protected by parents from injury in the home environment during this age, but the incidence of trauma from the age of 5 years and thereafter increases because of increasing activity.

In this study, both sexes were affected by trauma, with a male to female ratio of 3:2 [male: 18 (60%) patients, female: 12 (40%) patients], indicating the increasing rate of trauma in the male population than in the female population due to higher activity and greater involvement of boys in sports-related activities compared with girls.

Different etiologies for trauma were recorded, with fall from a height being the most common (12 patients), followed by motor car accidents (12 patients). The least common were sports-related injuries (four patients) and assault (two patients) (Figs 7 and 8).

Different fracture sites were recorded, with the highest incidence being mandibular fractures (18 patients) because of its prominent feature, followed by zygomatic complex fractures (five patients), orbital fractures (four patients), maxillary fractures (two patients) – one isolated and the other with mandibular fracture – and finally frontal bone and sinus fractures (one patient).

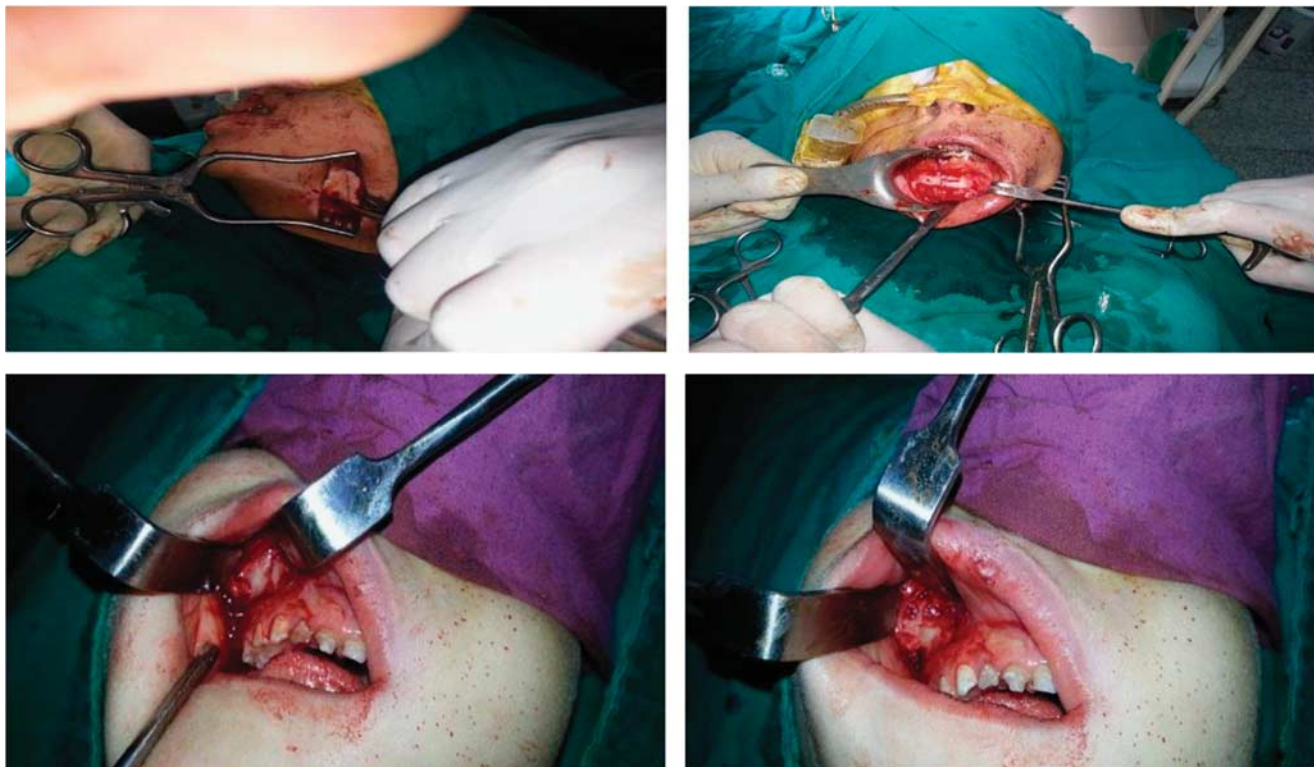
Patients with mandibular fractures

All mandibular fractures were treated with Inion CPS resorbable plates (2.5 mm) and screws (28 plates and 112 screws), except for fracture condyles (intracapsular), which underwent closed reduction only with short period of maxillomandibular fixation and intermittent elastics for 7–10 days postoperatively. Follow-up shows mild to moderate facial edema, mild intraoral ecchymosis, and mild infections healed with antibiotics; there was no extrusion of plates. In patients with condylar fractures, no airway compromise and normal occlusion was achieved after removal of arch bars (7–10 days) with good healing. Follow-up CT showed good bony union without any signs of instability, nonunion, or malunion, except for the drill holes for insertion of the screws wires. Fig. 9 shows postoperative CT for patient 10 and Fig. 10 shows normal mouth opening and occlusion.

Patients with zygomatic complex fractures

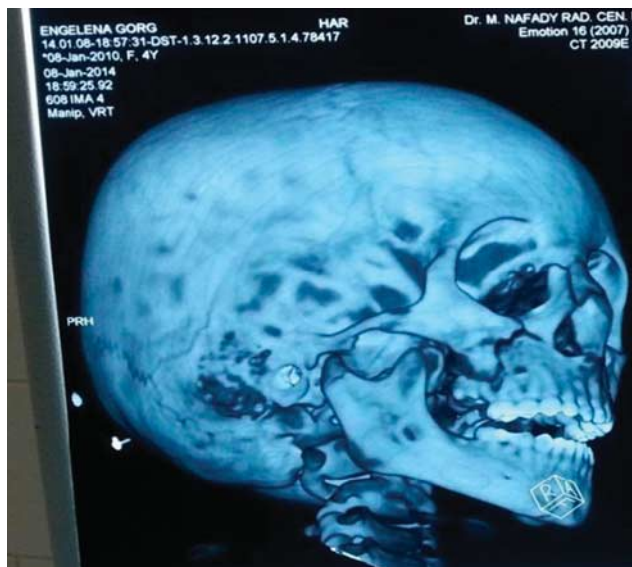Follow-up shows periorbital edema, periorbital ecchymosis, which persisted for 7 days, infraorbital nerve hypoesthesia, which persisted for 10 days, no diplopia, no enophthalmos, no antimongoloid slant, no flattening of malar eminence, and mild limitation of mouth opening. Fortunately, no infection or plate extrusion had occurred.

Fig. 4



Intraoperative view showing rt zygomatic fracture with resorbable plate fixation at zygomatic buttress.

Fig. 5



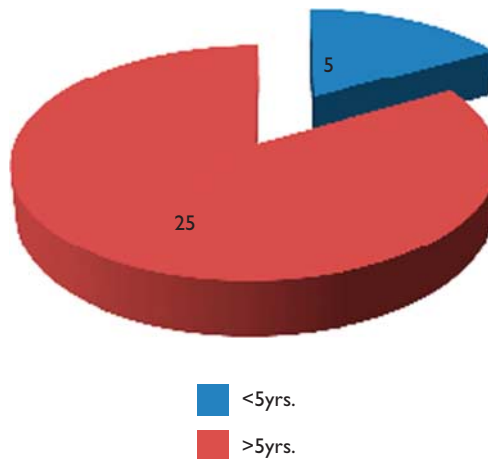
Computed tomography image showing the site of the fracture.

CT shows no bony healing complications (malunion, displacement), and there were no need for orbital floor reconstruction.

Patients with orbital fractures

Follow-up shows periorbital edema and ecchymosis, no diplopia, no enophthalmos, no limitation of eye move-

Fig. 6



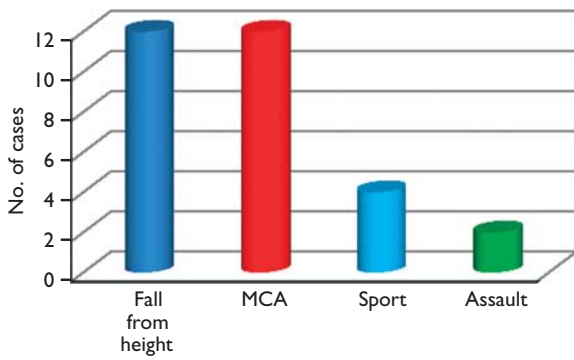
Age-related incidence of trauma.

ments, and no ocular dystopia, and radiologically shows fracture healing and reduction of herniated orbital contents from the maxillary sinus (no opacification of maxillary sinus, no tear drop sign).

Patients with maxillary fractures

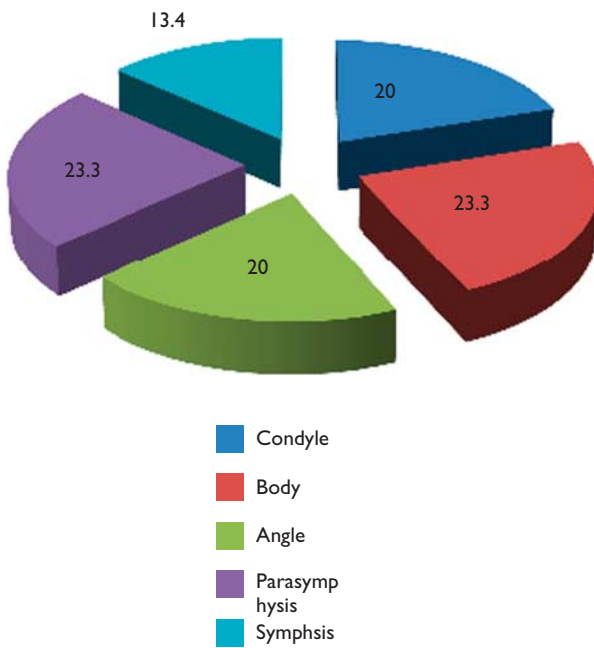
Follow-up showed clinically mild intraoral ecchymosis, presence of mild infection that healed with antibiotics after 7 days, no extrusion of plates, normal occlusion, no mouth deviation, and presence of abnormal bite. CT showed good bony healing (no malunion or nonunion).

Fig. 7



Frequency of mechanisms of trauma. MCA, middle cerebral artery.

Fig. 8



Percentages of types of mandibular fractures.

Patient with frontal sinus fracture

Follow-up showed clinically no cerebrospinal fluid leak or signs of meningitis, mucocele, or frontal sinusitis. CT showed good bony healing and no pneumcephalus or dural tears.

Discussion

Trauma is a healthcare problem in humans. Maxillofacial trauma in particular is a major component of trauma and causes severe mortality and morbidity [8]. Dentoalveolar and soft tissue injuries account for the majority of pediatric maxillofacial injuries but the frequency of facial fractures is considerably low [9]. Trauma to the facial region is especially significant because of the conspicuous location of the human face, its esthetic importance, and

psychological image adversely affecting important functions like speech, mastication, respiration, and deglutition [10].

In modern maxillofacial surgery, rigid osteosynthesis has become one of the major breakthroughs. For 25 years now, titanium has shown excellent qualities [11] and is currently regarded as the golden standard. When using metallic materials it is sometimes necessary to perform a second operation for removal of these screws. The disadvantages inherent in metallic materials are palpation, sensitivity, migration, obstruction in the radiographs, possible bone resorption, allergies, and growth delays in children, all of which encouraged the development of resorbable materials [12]. Since the introduction of biodegradable devices in 1966, the development of their mechanical properties and degradation characteristics has been extensive.

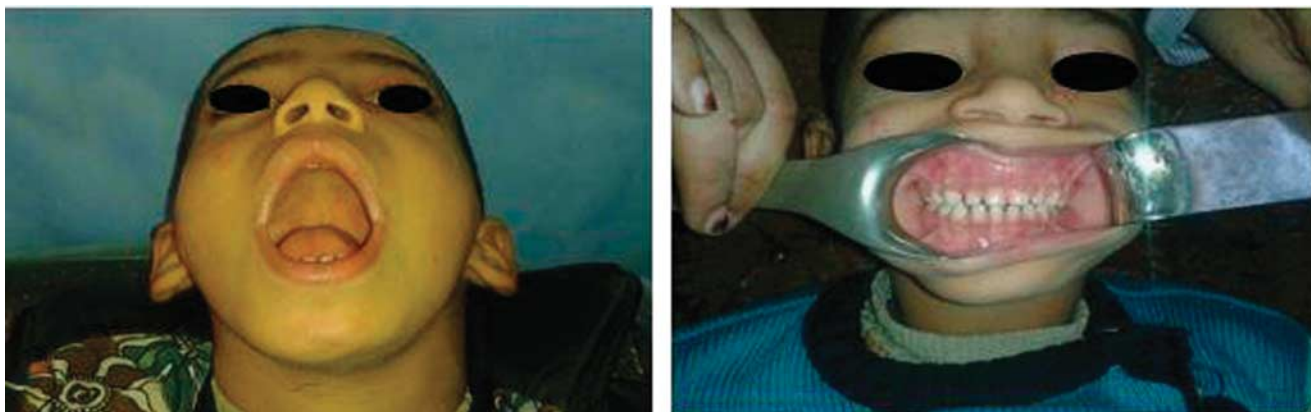Bioresorbable materials mostly used in maxillofacial surgery are a mixture of rigid and elastic polymers selected for their strength, malleability, and degradation properties. The degradation profiles have been tailored to provide initial stability and then progressively load bone to stimulate regeneration. The results of various studies suggested that the use of biodegradable fixation in selected patients with facial fractures is acceptable [7].

In the present study, 30 cases of maxillofacial fractures were treated with internal fixation using Inion CPS biodegradable plates and screws. There were 18 patients with mandibular fractures, five patients with zygomatic complex fractures, four patients with orbital fractures, two patients with maxillary fractures (one isolated and the other with mandibular fracture), and one patient with frontal bone and sinus fractures (anterior wall). Although the tensile strength of a biodegradable plate is less as compared with titanium, it provides enough stability to the fracture segments so that healing can take place.

In the present study, none of the patients had wound dehiscence and plate exposure in the postoperative period. This is somewhat contradictory to the incidence of wound dehiscence reported in the literature, which varies from 2% to as high as 6% [13]. These results can be attributed to the tight closure of the incision obtained with meticulous suturing, adequate soft tissue cover over the implant site, and newer thinner implants. No local tissue reaction and foreign body type of reaction was noticed in the evaluation of the surgical site during the follow-up period, which is contrary to the study by Wittwer *et al.* [14]. Although implant material could not be seen on radiographs, these were obtained in all patients postoperatively, at predecided follow-up intervals.

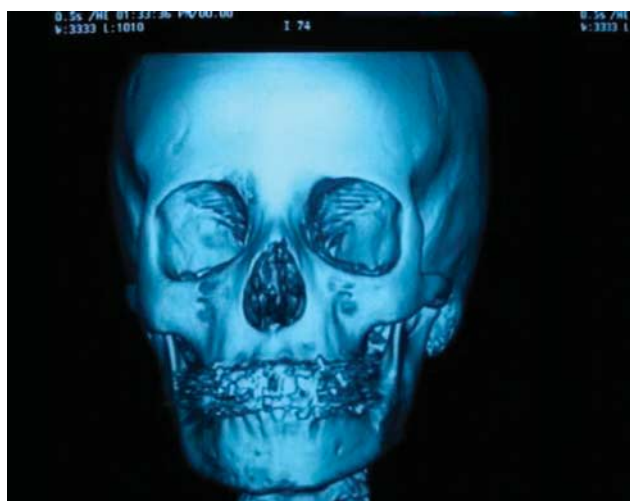Bali *et al.* [2] conducted a study on 10 patients with maxillofacial fractures treated with Inion CPS biodegradable plates: two patients with angle (10%) and parasymphysis (10%) fractures and eight patients with midface fractures, out of which five (50%) were zygomaticomaxillary complex fractures, two (20%) were Le Fort II, and one (10%) was a Le Fort III fracture. Reduction of the fracture segments was satisfactory and occlusion relationships were judged as normal in all cases

Fig. 9



Postoperative computed tomography of a patient.

Fig. 10



Normal mouth opening and occlusion.

at every follow-up. Adequate stability was maintained throughout the postoperative period in all patients (100%). There was no incidence (0%) of postoperative paraesthesia, diplopia, enophthalmos/ exophthalmos, wound dehiscence, or plate exposure. In one (10%) patient, signs of postoperative infection were noticed, including swelling and pain, which was managed conservatively with administration of oral antibiotics and analgesics.

Satisfactory reduction was seen in all patients, as judged by the position of fracture segments in postoperative radiographs and compared with all subsequently obtained images. The undisturbed reduction was considered a marker of the stable fixation provided by the bioresorbable system. The screw holes visible as radiolucencies on the radiograph were also seen to maintain their position throughout the observed period of follow-up. This again was considered a marker for maintenance of reduction, which is in accordance with the studies of Ferretti [15] and Bell *et al.* [7]. Rozema *et al.* [16] studied the effect of these plates and screws when radiation was applied. They

stated that these can be regarded as tissue equivalents that do not interfere with the dose distribution of radiotherapy and can safely be used for fracture fixation of bone segments when postoperative radiotherapy is needed.

Postoperative complications after facial fracture or repair are uncommon in children. Because of the child's greater osteogenic potential, faster healing response, and less frequent need for open reduction and rigid fixation, postoperative infections, malunions, and nonunions are all less frequent than that seen in the adult population [12].

Several clinical trials have shown the safety of absorbable fixation system in maxillofacial surgery. Observational studies in maxillofacial surgery have demonstrated that the bioresorbable plate leaves a stable bridge of healed bone or soft tissue after complete degradation with foreign-body reactions. In contrast, randomized, prospective controlled trials have shown no statistically significant differences in the incidence of material-related complications between the biodegradable and titanium groups [17].

However, Buijs *et al.* [18] reported that biodegradable plates and screws performed inferiorly to titanium plates and screws in malocclusion (11.1 vs. 8.8%), palpability plate/screw (50.4 vs. 38.1%), dehiscence (4.3 vs. 0%), abscess formation (9.4 vs. 3.5%), and inflammatory reactions (17.1 vs. 7.1%). In addition, absorbable fixation systems cost more in clinical use.

Bioresorbable fracture fixation has been in clinical use in humans for 25 years. Still, there are apprehensions regarding the use of these materials and they have not been able to find place in the armamentarium of the common practicing surgeon. Their exorbitant cost and questionable ability to be used in load-bearing areas remain a major hurdle. Its effects on growth may need longer periods of follow-up. Another significant factor of the limited use is the resistance by surgeons to modify their conventional, well-experienced, treatment techniques. However, if these problems could be completely

overcome and these implants could offer the same benefits as metallic implants, they would be able to find a greater place in craniofacial fracture fixation [17].

Conclusion

- (1) The Inion CPS biodegradable fixation system provided satisfactory stabilization when used as internal fixation for pediatric maxillofacial fractures.
- (2) The Inion CPS biodegradable implant material did not evoke any significant immune response and is nontoxic.
- (3) The fixation system did not alter the healing process.
- (4) The fixation technique was not difficult to handle.
- (5) A second surgical procedure was not carried out in any of the patients to remove the implant as the biodegradable implant resorbed over a period of time. This is more beneficial in the case of children where removal of a metallic implant is recommended even in asymptomatic cases because of growth restrictions.
- (6) The encouraging results as obtained in this study seem to reinforce the use of biodegradable plates and screws in the fixation of maxillofacial fractures.

Acknowledgements

Conflicts of interest

There are no conflicts of interest.

References

- 1 Meier JD, Travis T. Tollefson pediatric facial trauma. *Curr Opin Otolaryngol Head Neck Surg* 2008; **16**:555–561.
- 2 Bali RK, Sharma P, Jindal S, Gaba S. To evaluate the efficacy of biodegradable plating system for fixation of maxillofacial fractures: a prospective study. *Natl J Maxillofac Surg* 2013; **4**:167–172.
- 3 Turvey TA, Proffit WP, Phillips C. Biodegradable fixation for craniomaxillofacial surgery: a 10-year experience involving 761 operations and 745 patients. *Int J Oral Maxillofac Surg* 2011; **40**:244–249.
- 4 Suuronen R, Haers PE, Lindqvist C, Sailer HF. Update on bioresorbable plates in maxillofacial surgery. *Facial Plast Surg* 1999; **15**:61–72.
- 5 Enislidis G, Pichorner S, Lambert F, Wagner A, Kainberger F, Kautzky M, et al. Fixation of zygomatic fractures with a new biodegradable copolymer osteosynthesis system: Preliminary results. *Int J Oral Maxillofac Surg* 1998; **27**:352–355.
- 6 Wood GD. Inion biodegradable plates: the first century. *Br J Oral Maxillofac Surg* 2006; **44**:38–41.
- 7 Bell RB, Kindsfater CS. The use of biodegradable plates and screws to stabilize facial fractures. *J Oral Maxillofac Surg* 2006; **64**:31–39.
- 8 Singh G, Mohammad S, Chak RK, Lepcha N, Singh N, Malkunje LR. Bio-resorbable plates as effective implant in paediatric mandibular fracture. *J Maxillofac Oral Surg* 2012; **11**:400–406.
- 9 Ferreira PC, Amarante JM, Silva PN, Rodrigues JM, Choupina MP, Silva AC, et al. Retrospective study of 1251 maxillofacial fractures in children and adolescents. *Plast Reconstr Surg* 2005; **115**:1500–1508.
- 10 Gassner R, Tuli T, Hachl O, Rudisch A, Ulmer H. Cranio-maxillofacial trauma: a 10 year review of 9543 cases with 21,067 injuries. *J Craniomaxillofac Surg* 2004; **31**:51–61.
- 11 Kambalimath HV, Agarwal SM, Kambalimath DH, Singh M, Jain N, Michael P. Maxillofacial injuries in children: a 10 year retrospective study. *J Maxillofac Oral Surg* 2013; **12**:140–144.
- 12 Araujo MM, Waite PD, Lemons JE. Strength analysis of Le Fort I osteotomy fixation: titanium versus resorbable plates. *J Oral Maxillofac Surg* 2001; **59**:1034–1039.
- 13 Yerit KC, Enislidis G, Schopper C, Turhani D, Wanschitz F, Wagner A, et al. Fixation of mandibular fractures with biodegradable plates and screws. *Oral Surg Oral Med Oral Pathol Oral Radiol Endod* 2002; **94**:294–300.
- 14 Wittwer G, Adeyemo WL, Yerit K, Voracek M, Turhani D, Watzinger F, et al. Complications after zygoma fracture fixation: is there a difference between biodegradable materials and how do they compare with titanium osteosynthesis? *Oral Surg Oral Med Oral Pathol Oral Radiol Endod* 2006; **101**:419–425.
- 15 Ferretti C. A prospective trial of poly-L-lactic/polyglycolic acid copolymer plates and screws for internal fixation of mandibular fractures. *Int J Oral Maxillofac Surg* 2008; **37**:242–248.
- 16 Rozema FR, Levendag PC, Bos RR, Boering G, Pennings AJ. Influence of resorbable poly (L-lactide) bone plates and screws on the dose distributions of radiotherapy beams. *Int J Oral Maxillofac Surg* 1990; **19**:374–376.
- 17 Yoshioka I, Igawa K, Nagata J, Yoshida M, Ogawa Y, et al. Comparison of material-related complications after bilateral sagittal split mandibular setback surgery: biodegradable versus titanium miniplates. *J Oral Maxillofac Surg* 2012; **70**:919–924.
- 18 Buijs GJ, Van BNB, Jansma J, de Visscher JG, Hoppenreijts TJ, et al. A randomized clinical trial of biodegradable and titanium fixation systems in maxillofacial surgery. *J Dent Res* 2012; **91**:299–304.